

اعوذ بالله من الشيطان الرجيم

لَقَدْ خَلَقْنَا الْإِنْسَانَ فِي

أَحْسَنِ تَقْوِيمٍ

﴿٤ التين﴾

# Retention in Orthodontic

- 1 Retention of the appliance inside the patient mouth
- 2 Retention of the components of the orthodontic appliance
- 3 Retention after completion of orthodontic treatment**

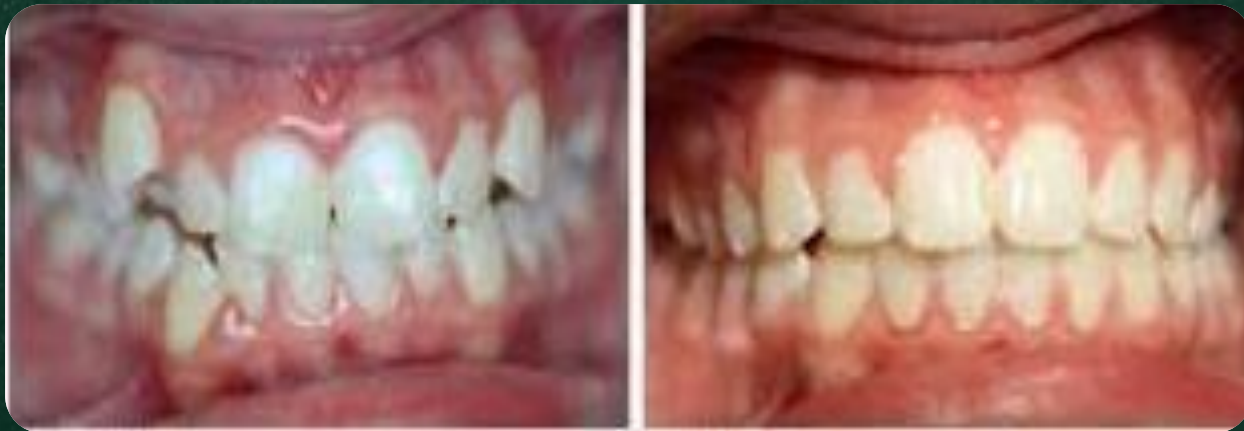# Introduction

One of the commonest risks of orthodontic treatment is **relapse**. Orthodontists use orthodontic retention to try and minimize this relapse.

Orthodontic retention needs to be planned and discussed with the patient as part of the initial treatment plan

# Retention after completion of orthodontic treatment

The aim of  
Retention after completion of orthodontic treatment is to prevent  
**Relapse**



**Before**

**After**

# Relapse

- Relapse = **retrogression** or **return to origin**

## Definition of relapse

Relapse is officially defined by the British Standards Institute **as the return**, following correction, of the features of the original malocclusion.

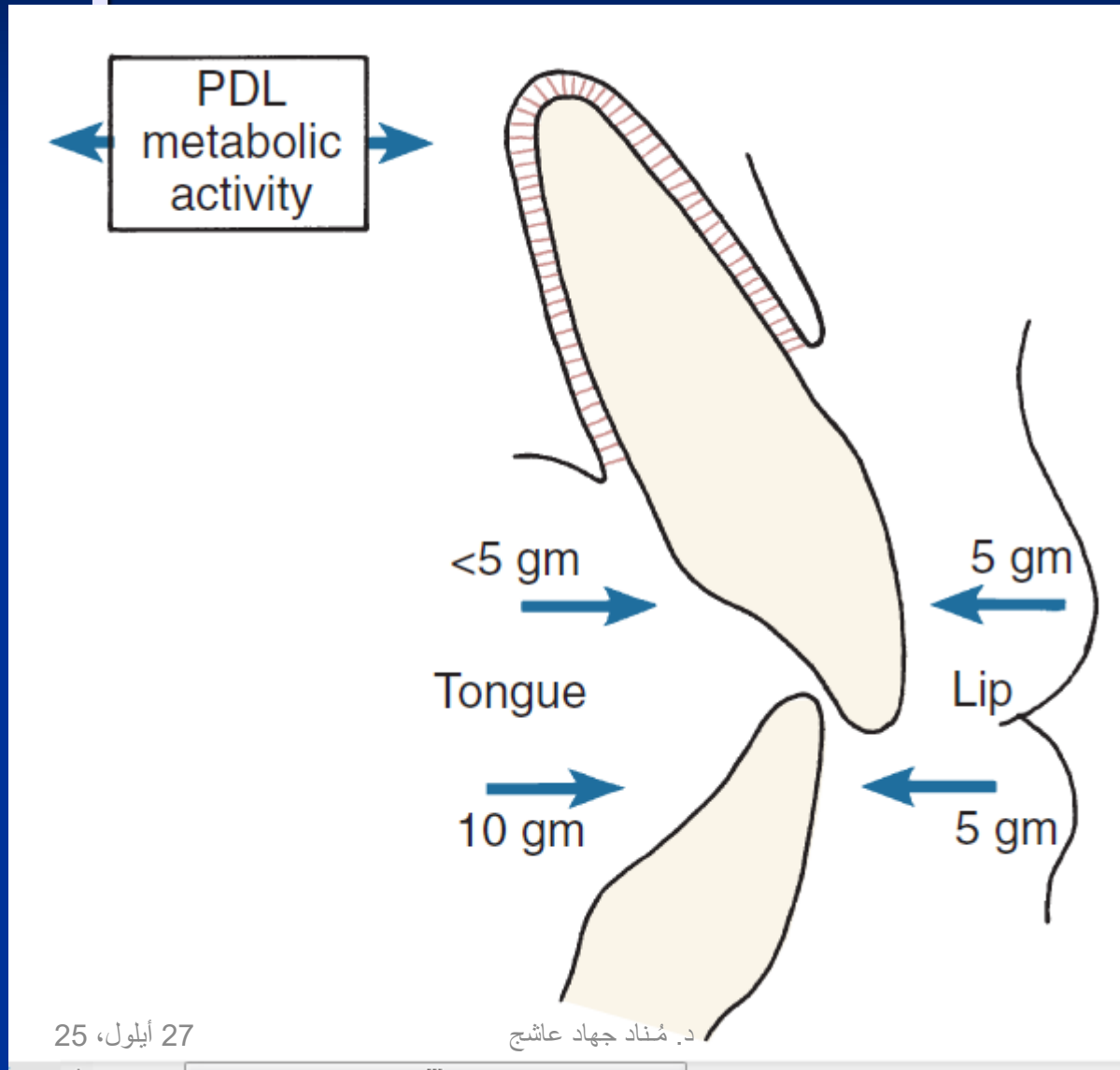
However, for patients, relapse is perhaps better described as any change from the final tooth position at the end of treatment. This may be a return towards the original malocclusion, but may also be movement caused by age changes and unrelated to the orthodontic treatment

# Stability



*what makes teeth instable  
after orthodontic treatment?*

# Neutral zone: Soft Tissue Equilibrium Pressures



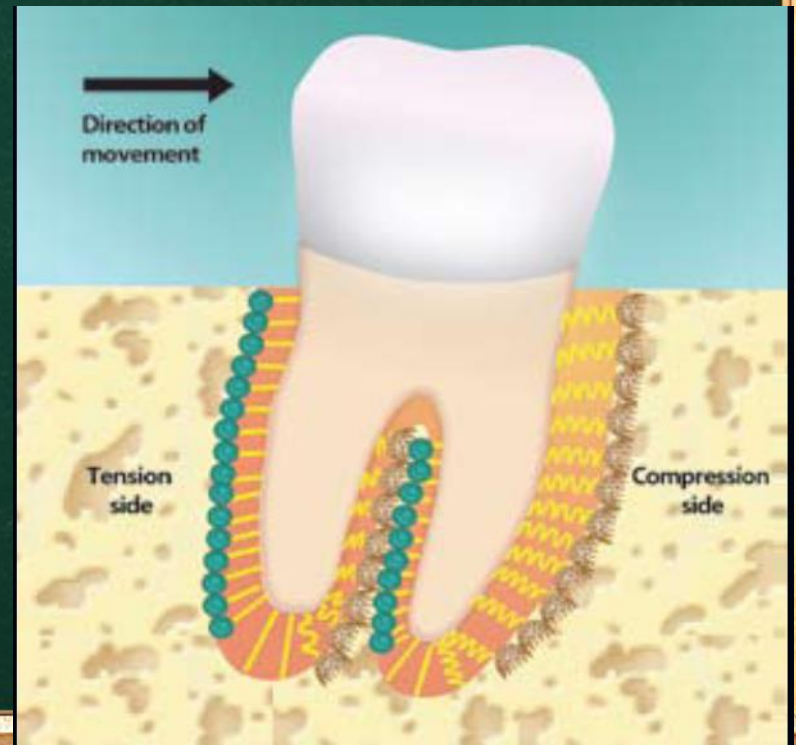
# Etiology of relapse

1

## Gingival and periodontal factors

When teeth are moved the periodontal ligament and associated alveolar bone remodels.

Until the periodontium adapts to the new position,.



# Etiology of relapse

1

## Gingival and periodontal factors

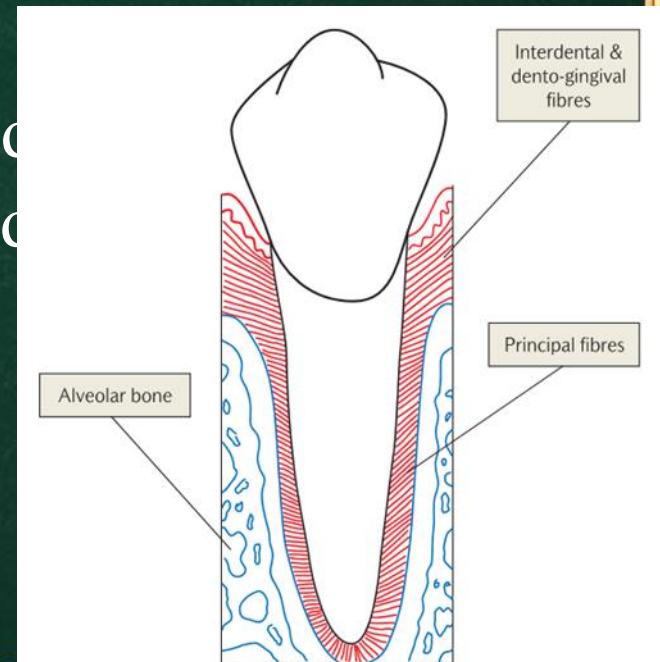
there is a tendency for the stretched periodontal fibers to pull the tooth back to its original position.

alveolar bone remodels within a **month**,

the principal fibers rearrange in **3–4 months**

collagen fibers in the gingivae re-organize after **4–6 months**.

elastic fibers in the dento-gingival and  
can take more than **8 months** to remodel.



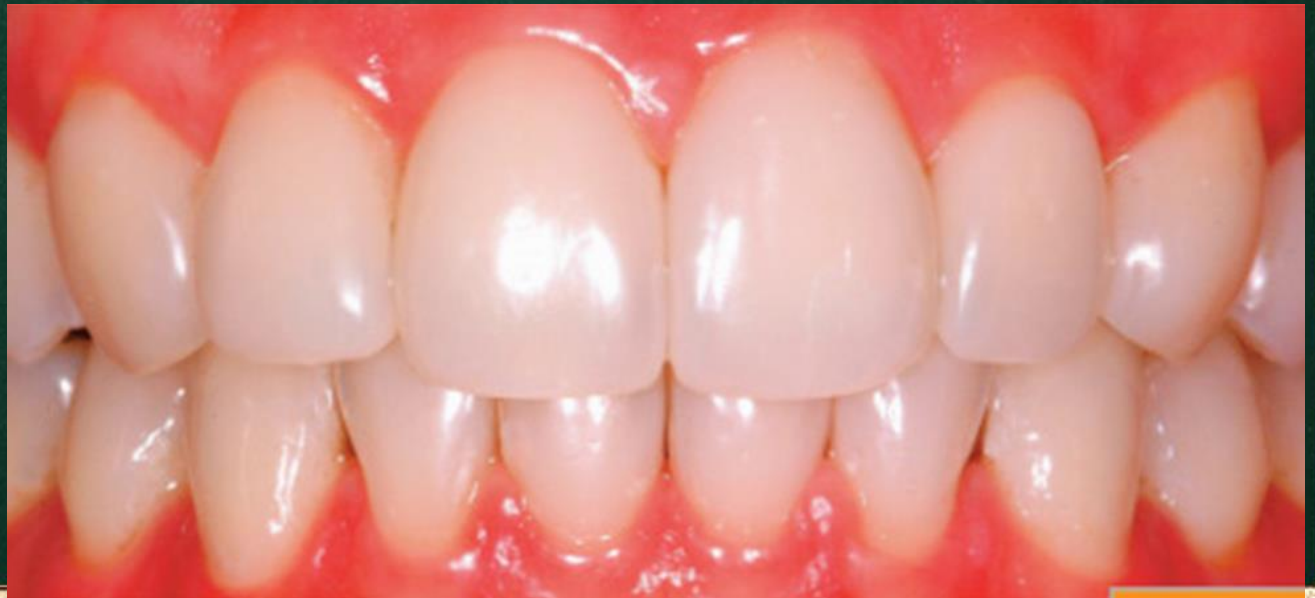# Etiology of relapse

2

## Occlusal factors

The way the teeth occlude at the end of treatment may affect stability.

It has been suggested that if the teeth interdigitate well at the end of treatment then the result is likely to be more stable.




# Etiology of relapse

2

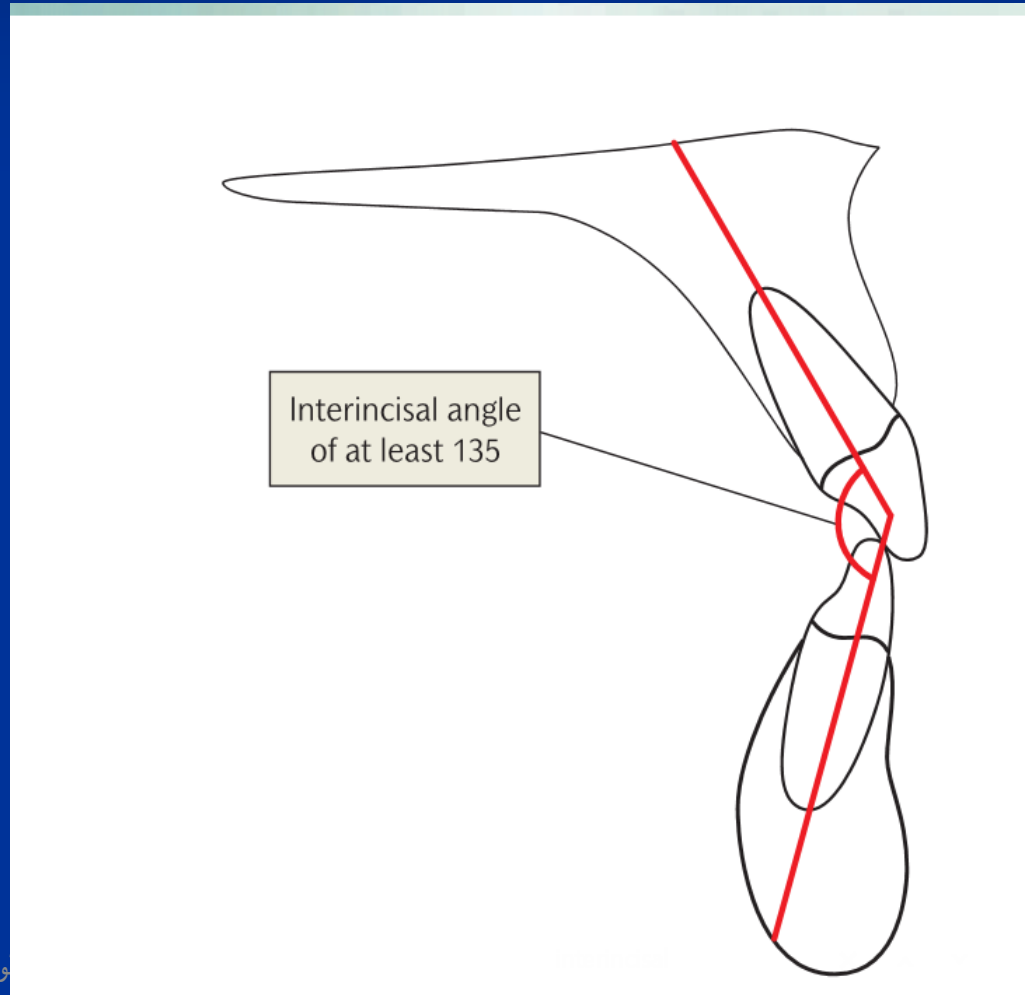
## Occlusal factors

When a deep overbite is corrected it has been shown that stability is increased if the lower incisor edge lies 0–2 mm anterior to the mid-point of the root axis of the upper incisor, known as **the centroid**.



# Inter-incisal angle

It is also desirable to have a favorable inter-incisal angle close to  $135^\circ$ , to produce a strong occlusal stop and prevent the incisors erupting past each other



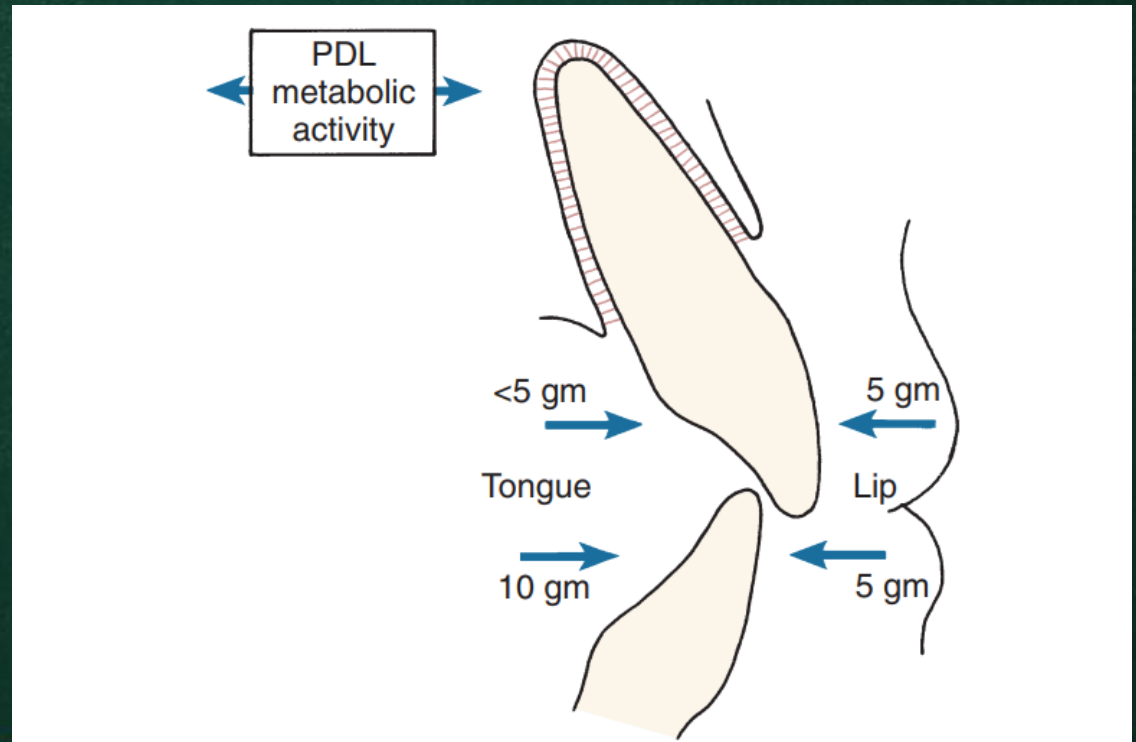
### 3

## Etiology of relapse

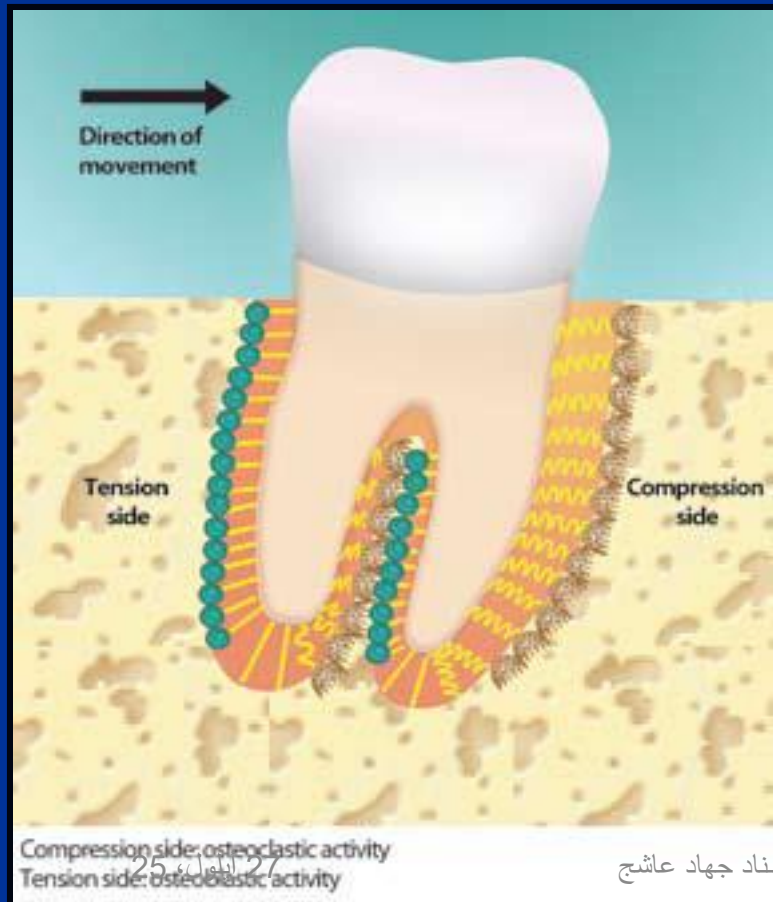
# Soft tissues

The teeth lie in an area of balance between the tongue on the lingual aspect and the cheeks and lips on the buccal and labial aspect. This area of balance is sometimes referred to as the neutral zone.

the neutral zone will change with age.



# Forces of surrounding tissues



Melrose & Millett  
1998

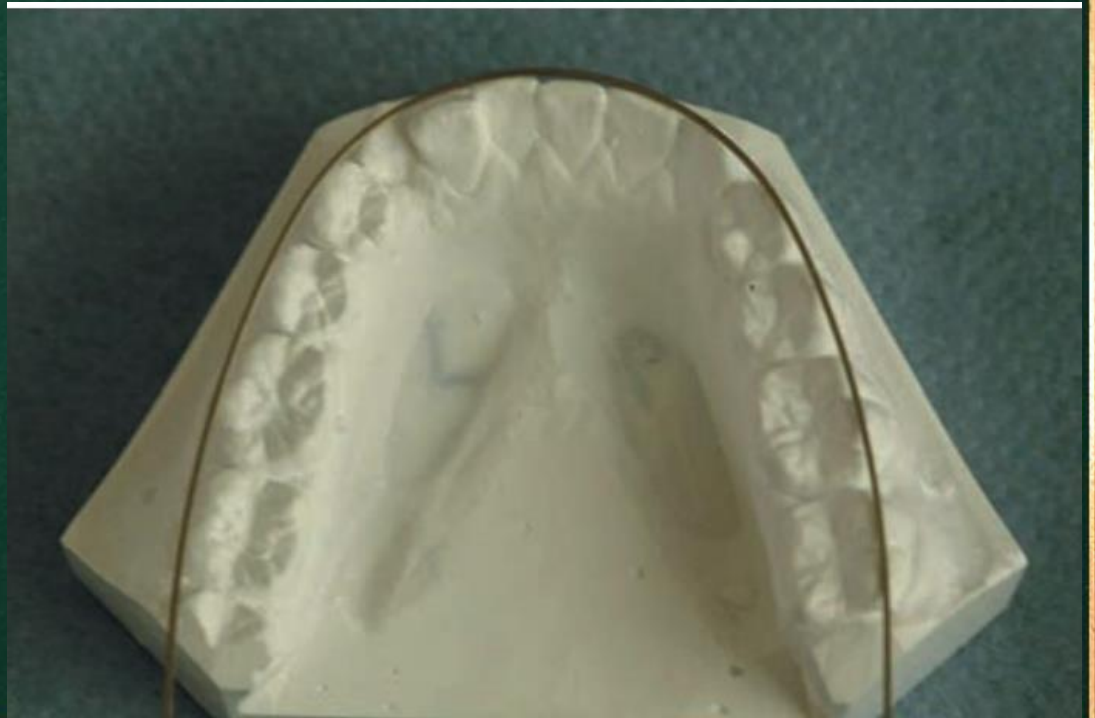

## Etiology of relapse

### 3

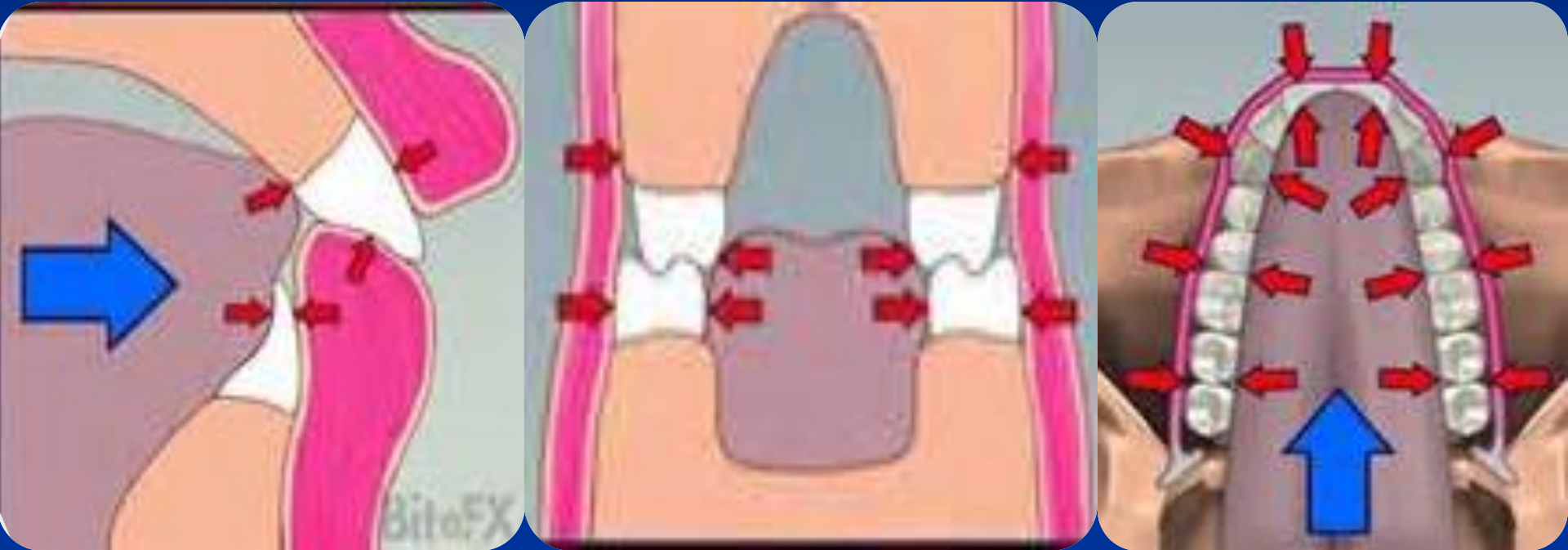
## Soft tissues

Where possible the original lower archform is therefore maintained throughout treatment, and the upper archform is then planned around the lower



# Imbalanced oral environment

Proffit *et al*, 2013 (equilibrium theory)



Lopez-Areal *and* Gandia 2013

# Etiology of relapse

## 4

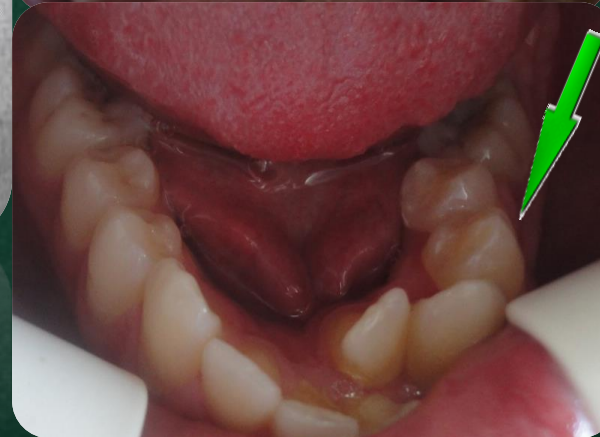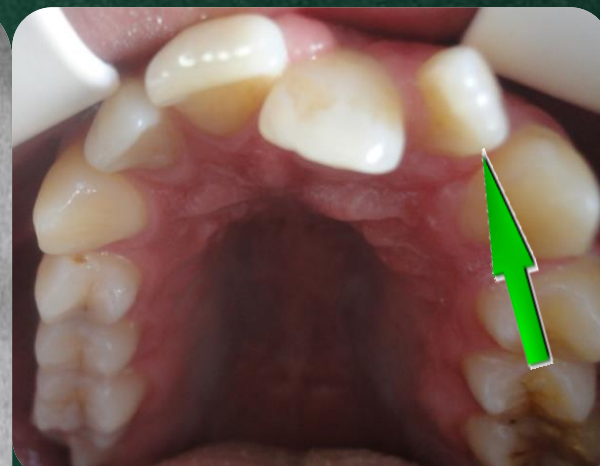
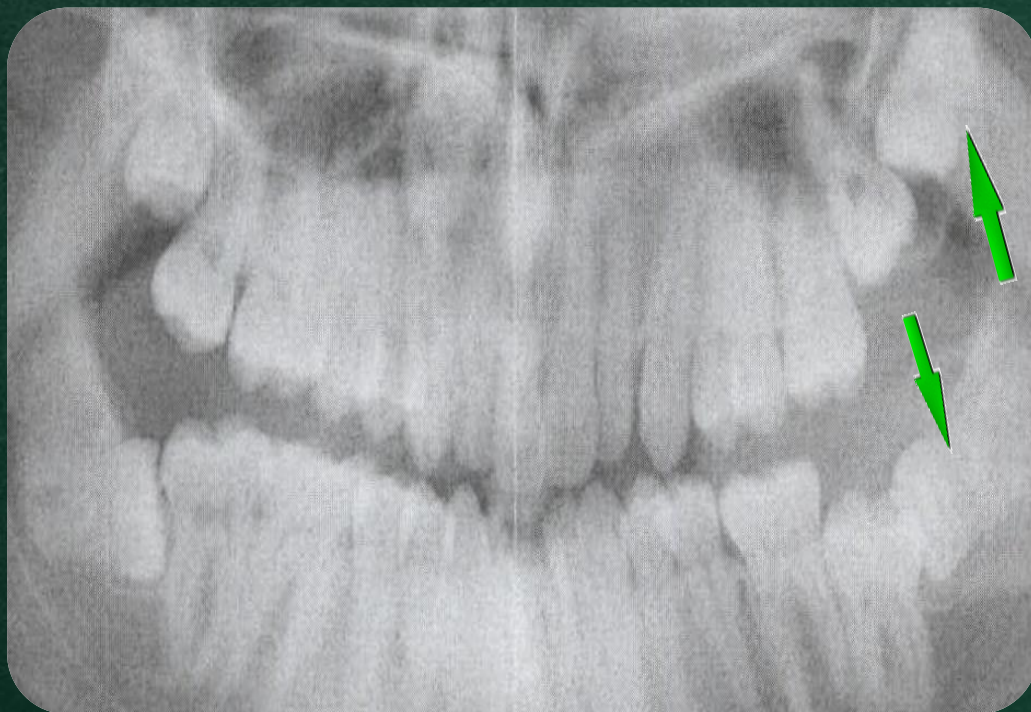### Growth

Although the majority of a patient's growth is complete by the end of puberty, it is now known that small age changes may be occurring throughout life. Subtle changes in the relative positions of the maxilla and the mandible mean that the oral environment and therefore the pressures on the dentition are constantly changing. If the pressures on the teeth are always changing, then it is perhaps not surprising that there is a risk of relapse of the teeth as the patient gets older.

# Etiology of relapse

5

Role of third molar



Richardson, 1989



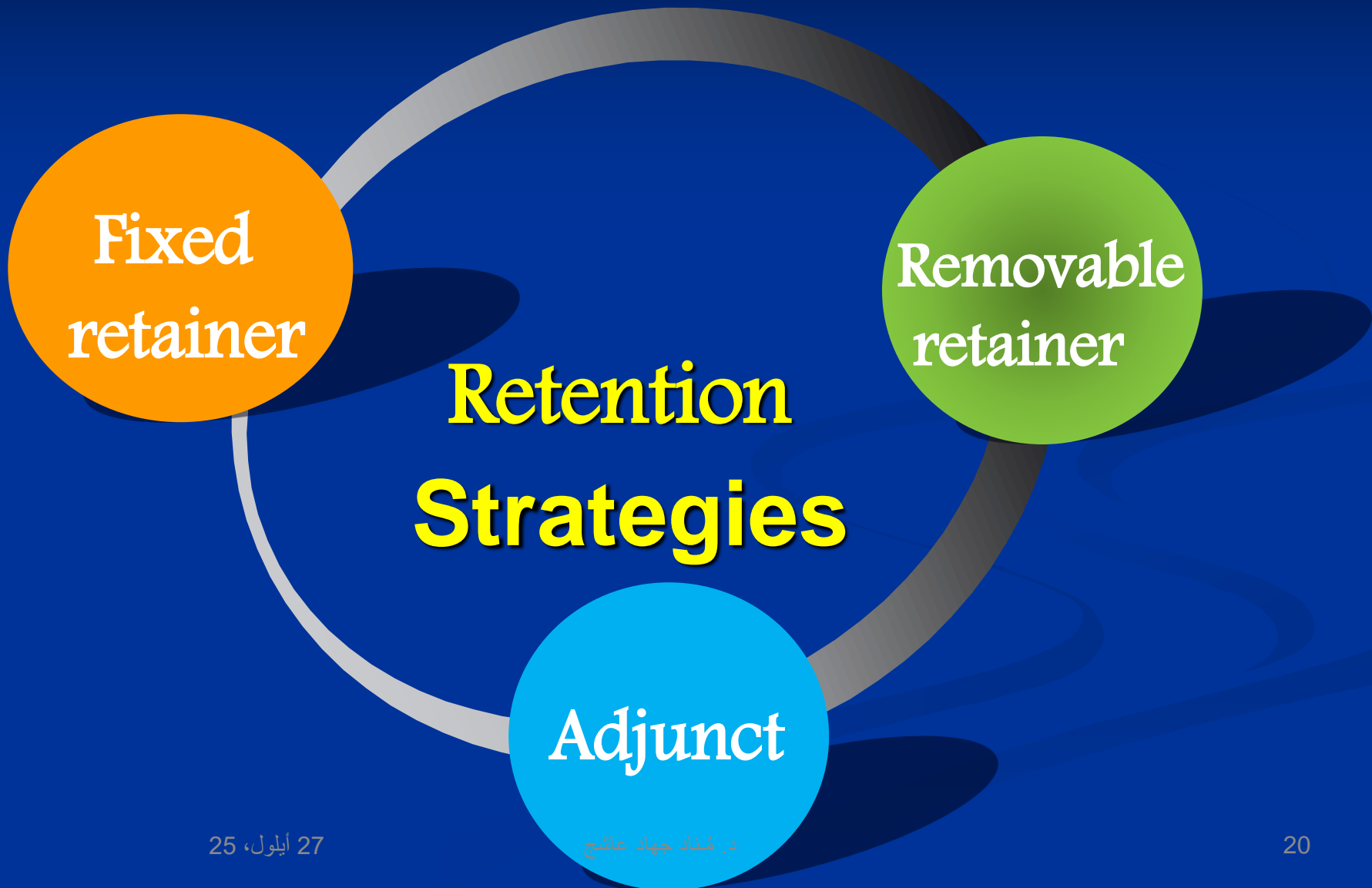
Blake and Bibby 1998



# Retention

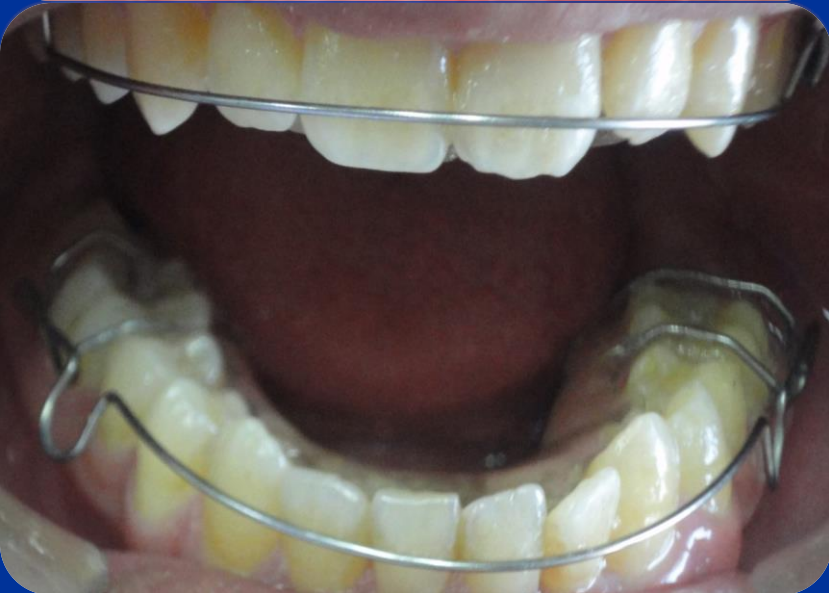
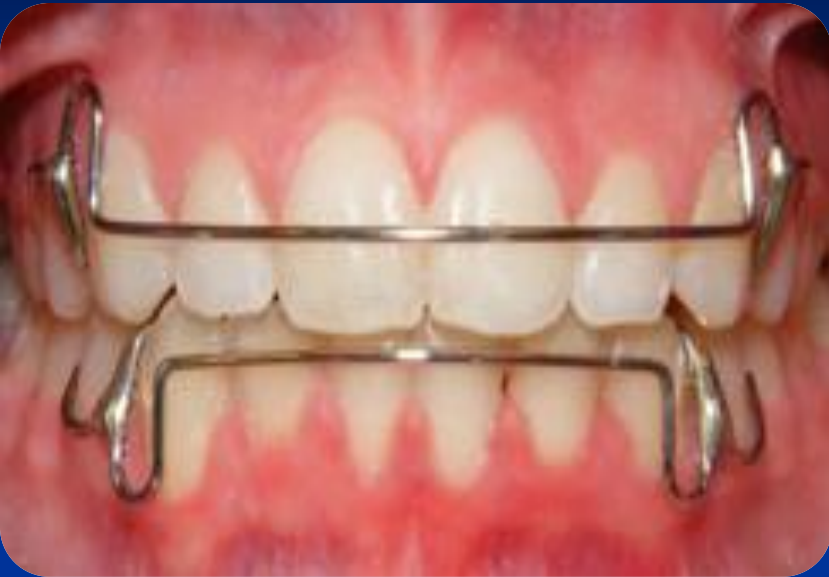
# Solutions = Retention



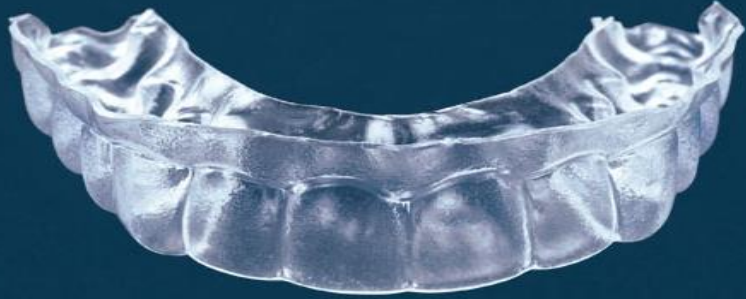
# Removable retainers

## Hawley retainer



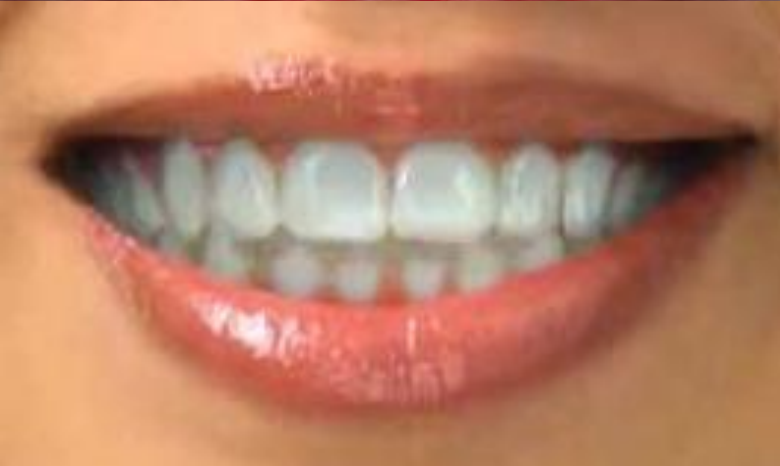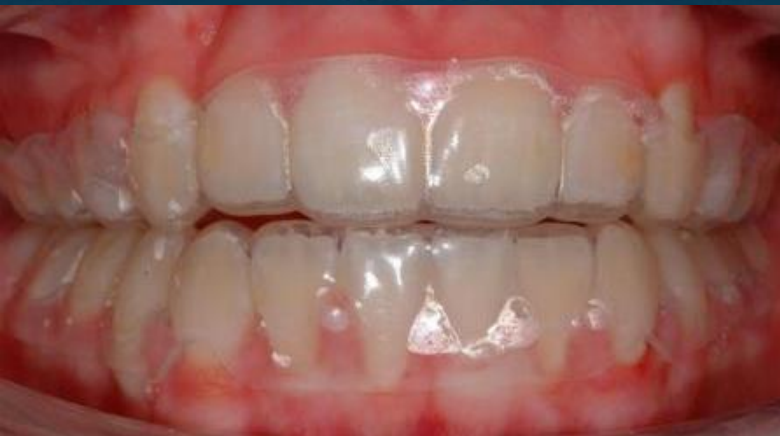# Removable retainers

## Vacuum-formed, Essix (invisible retainer)

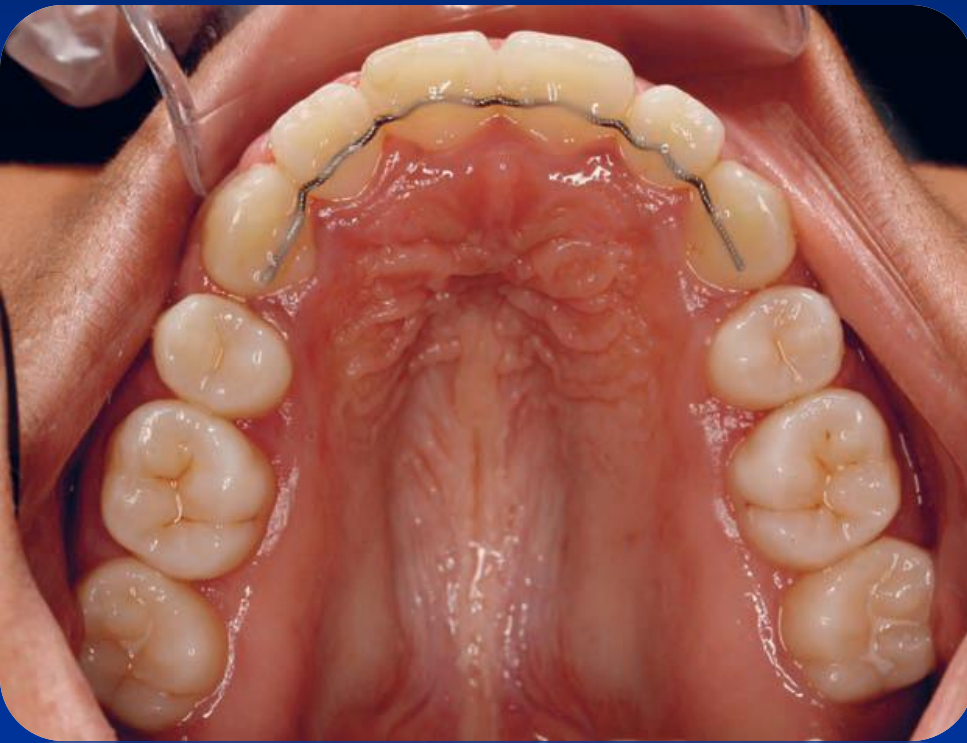

Vacuum-formed retainers offer a number of potential advantages over Hawley retainer

- Superior aesthetics
- Less interference with speech
- More economical and quicker to make
- Less likely to break
- Ease of fabrication
- Superior retention of the lower incisors



# Fixed retainers



Lyotard et al. (2010) ✓

Proffit et al. (2013) ✓

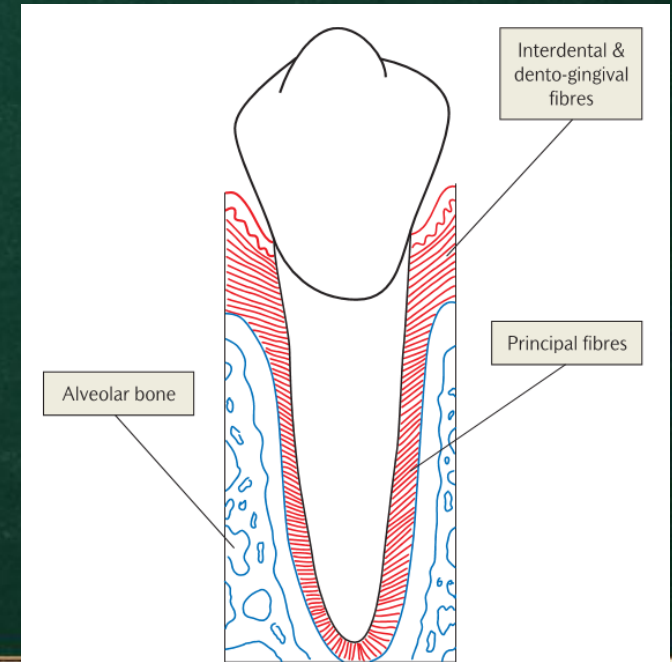
# Adjunctive techniques used to reduce relapse

- ❑ Pericision
- ❑ Enamel interproximal stripping

# Surgery

## Pericision

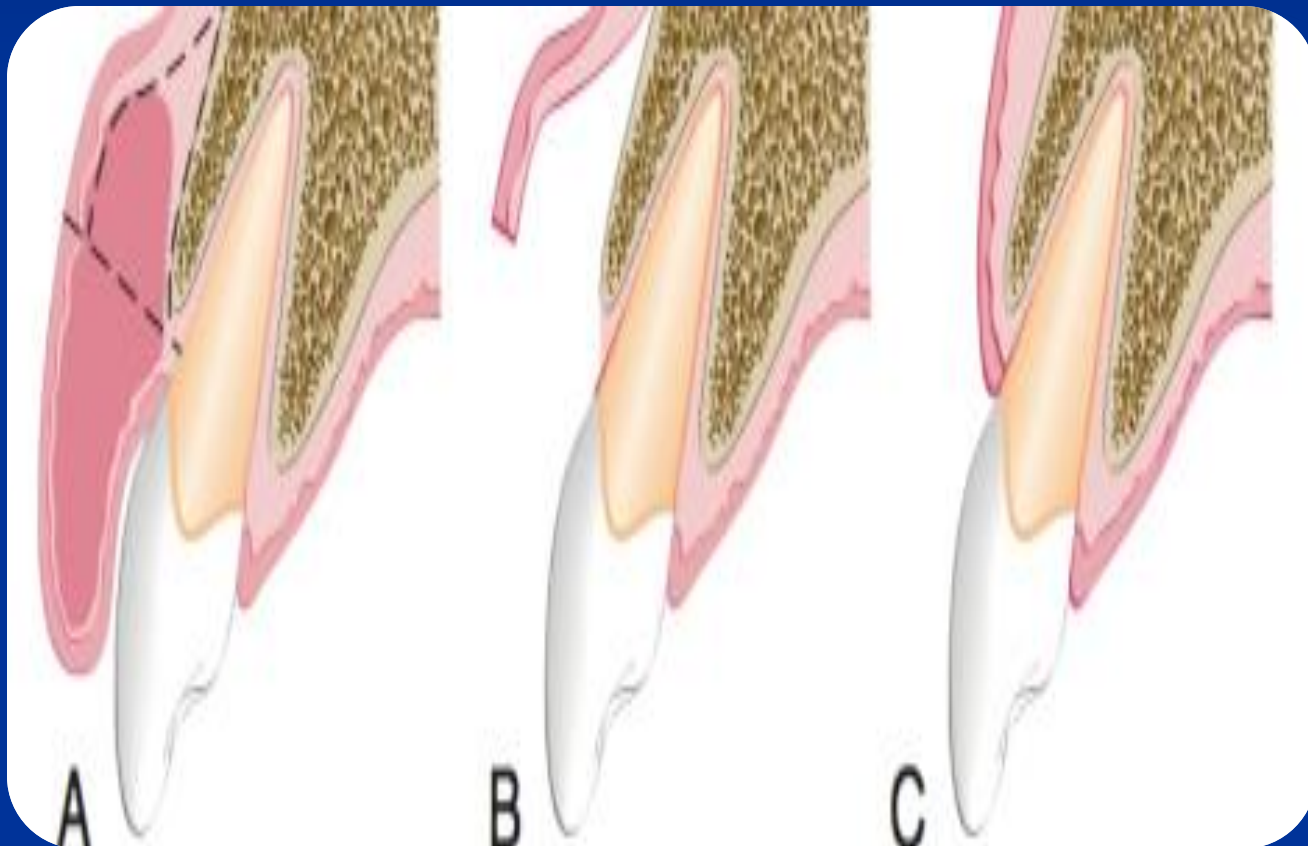
The elastic fibers within the interdental and dento-gingival fibers have a tendency to pull the teeth back towards their original position. This is particularly true with teeth that have been derotate.



Gingival and periodontal fibres

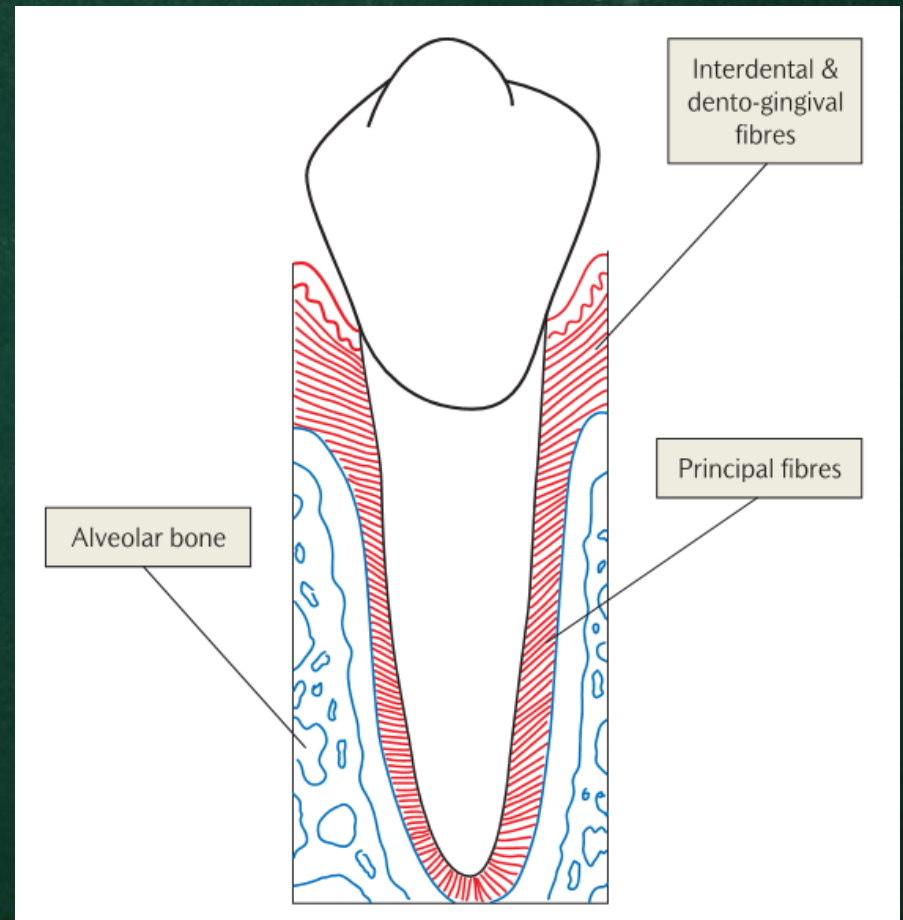
# Surgery

## Fibrotomy



# Pericision

This is also known as circumferential supracrestal fiberotomy. The principle is to cut the interdental and dento-gingival fibres above the level of the alveolar bone.

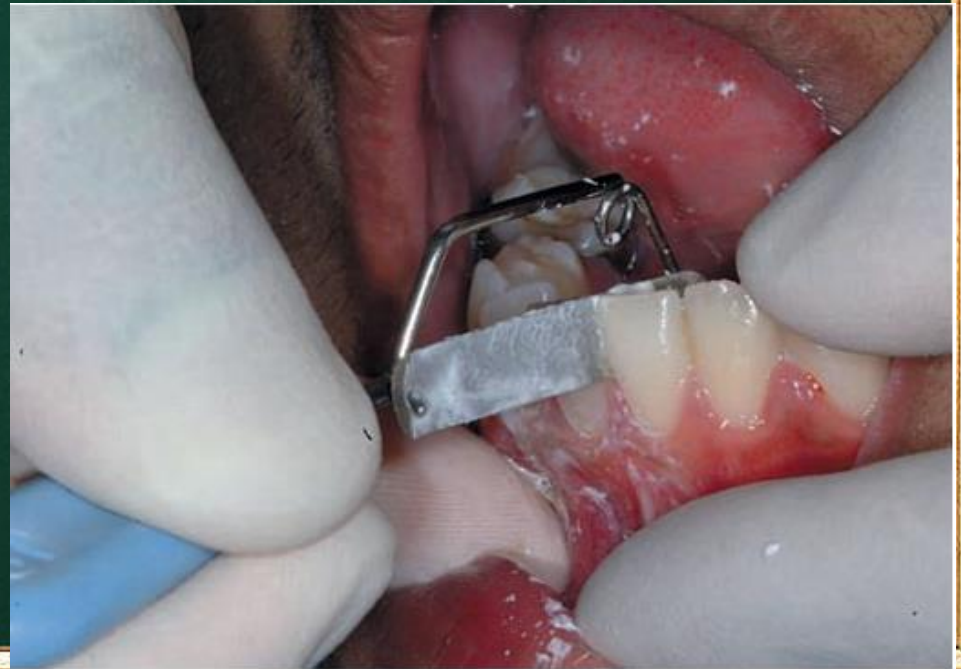

Gingival and periodontal fibres

# Enamel interproximal stripping

this is also known as reproximation . The removal of small amounts of enamel mesio-distally has been used to reshape teeth and to create small amounts of space. It is not clear why this process can reduce relapse. It has been suggested that by flattening the interdental contacts, **this will increase the stability between adjacent teeth**. It may also be the case that by removing small amounts of tooth tissue any minor crowding is relieved, avoiding possible proclination of the lower labial segment and increase in the intercanine width, both of which are potentially unstable movements

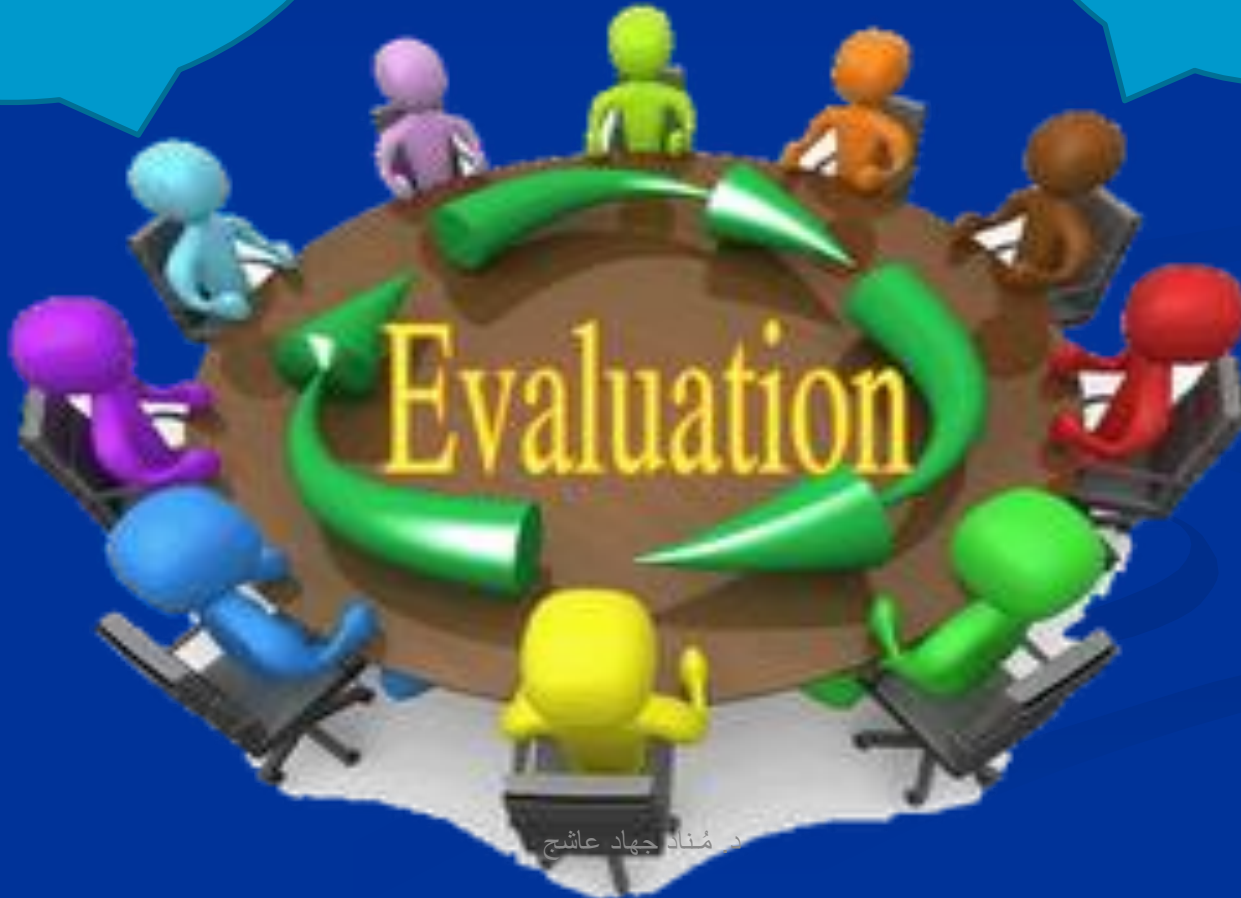Interproximal stripping  
using abrasive strips.



Orthodontist

Relapse is  
problem

Patient

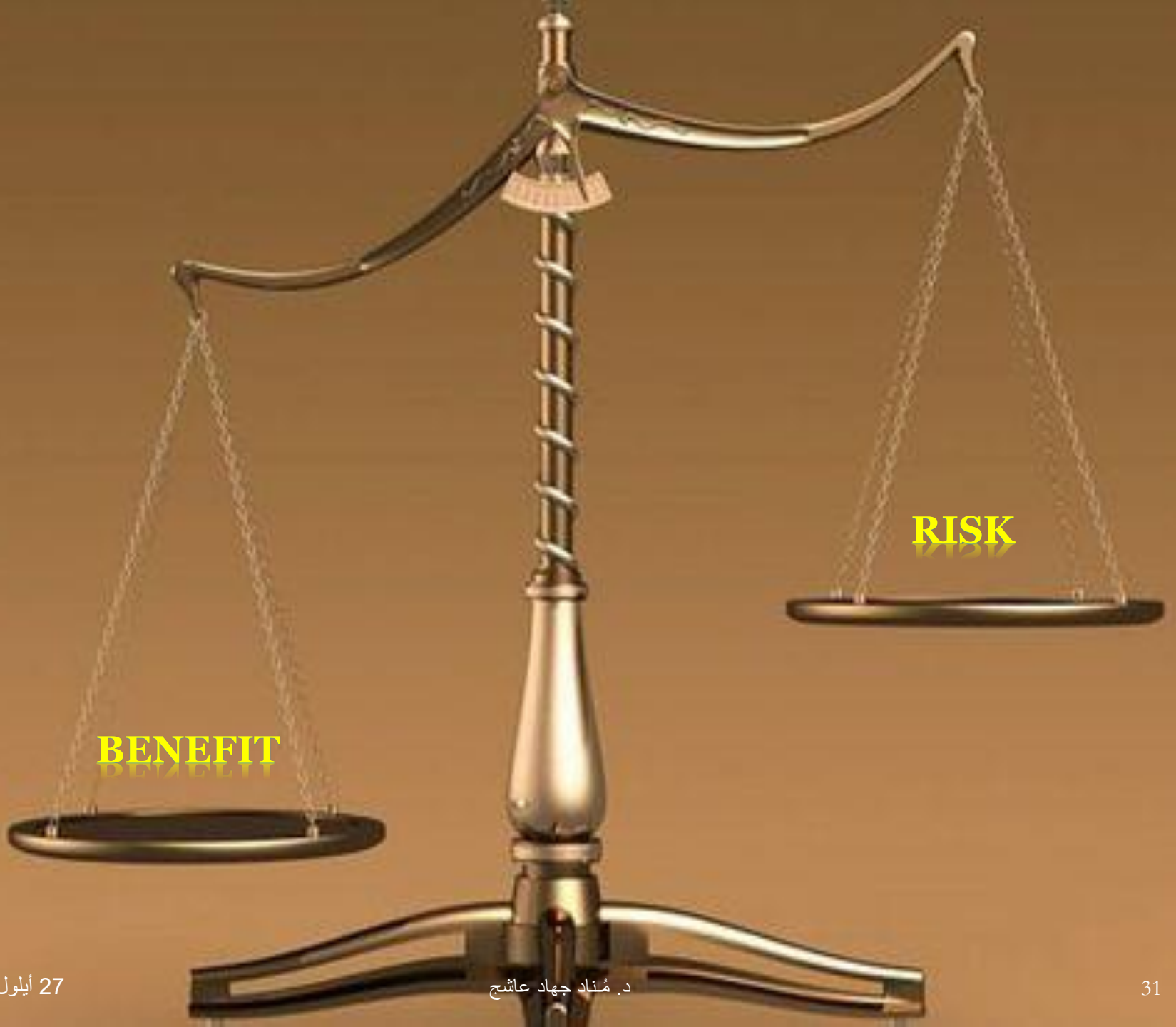



**PLEASE  
NOTE:**


## Important notes

- ❑ Retention is an important part of almost every case of orthodontic treatment. **This is because relapse is an unpredictable risk.**
- ❑ The patient needs to be made aware of the long-term risk of relapse and informed of ways of reducing the risk of this relapse. This should be discussed before treatment.





# CONCLUSION

- Appliance removal **#** finished case
- Retention  stability
- Fixed retainer = **most effective**