

Dental Terminology

Oral and Maxillofacial Surgery

Haider Nawfal

Reda diaa

Ahmed Bilal

Ahmed Falah

Procedures Involved in Maxillofacial Surgery

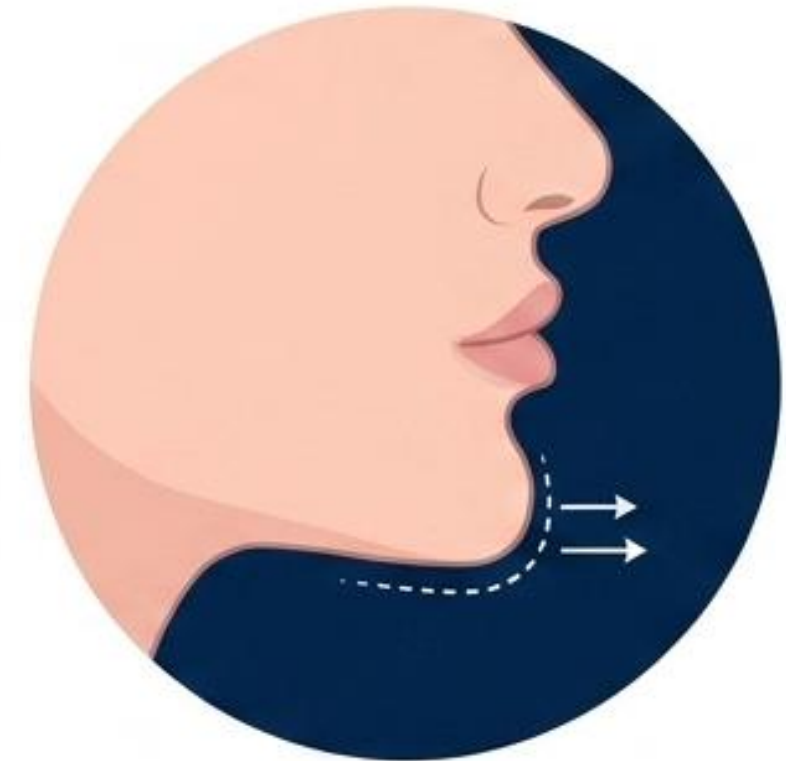Genioplasty:	plastic surgery of the chin.
Macrogenia:	large or excessive chin.
Microgenia:	an undersized chin.
Asymmetrical:	lack of balance of size and shape on opposite sides.
Pseudomacrogenia	is an excess of soft tissue, presenting a chin with the look of abnormal size. "Witch's chin" is soft tissue ptosis (dropping or sagging of an organ).
Osteotomy	(bone incision) is the surgical movement of bone.
Osteoplasty:	(to form bones) removal of bone, usually completed with surgical burs.

Chin augmentation

- moving the chin forward by making an incision inside the lower lip
- inserting an artificial chin implant or move the severed bone tip segment forward.



Before



After

Dental Terminology

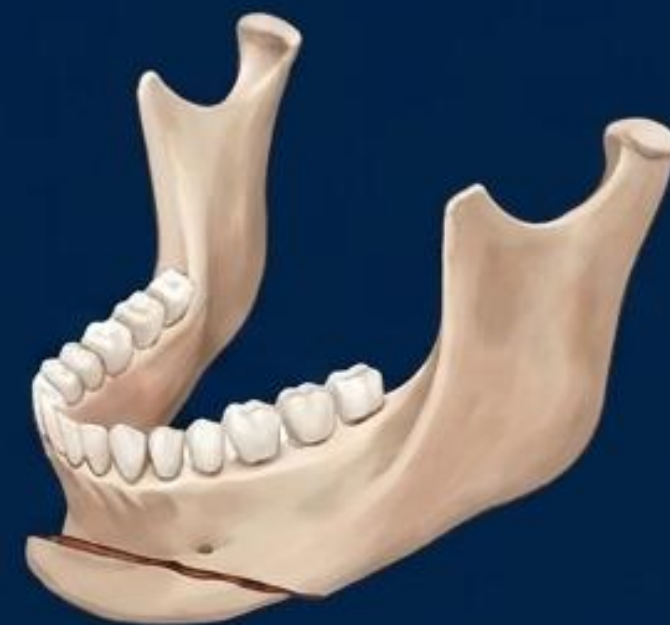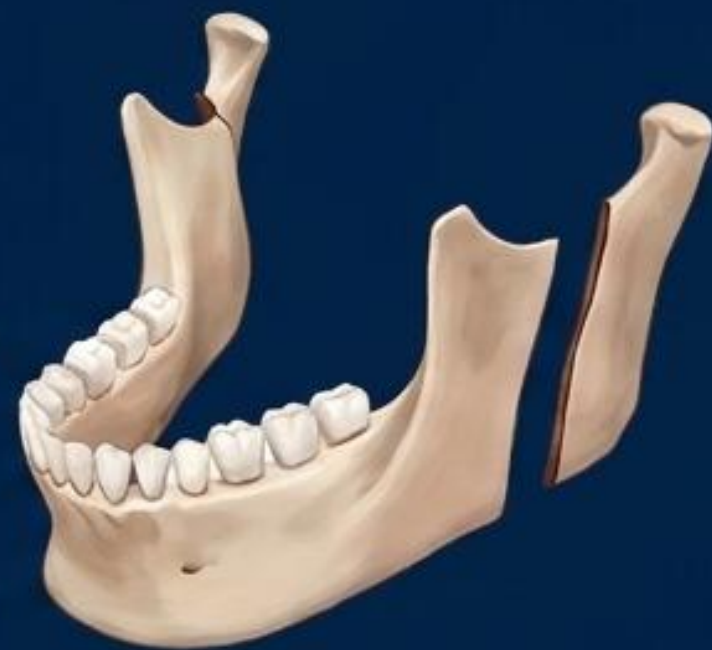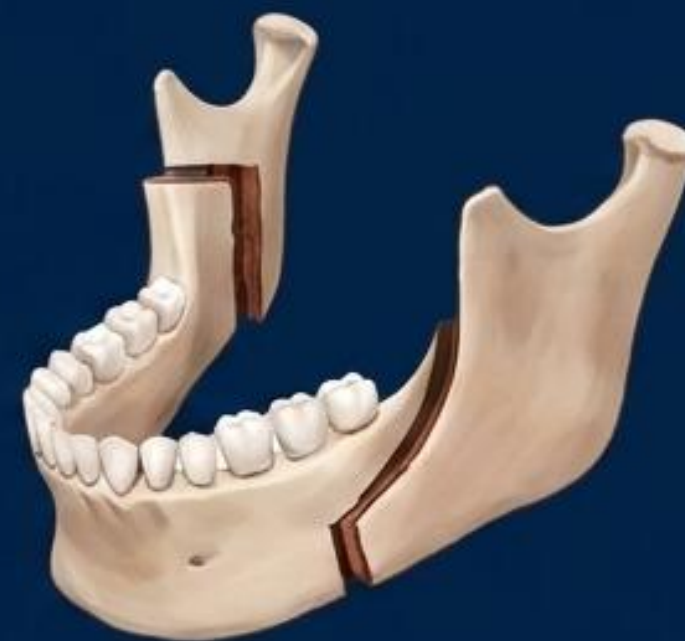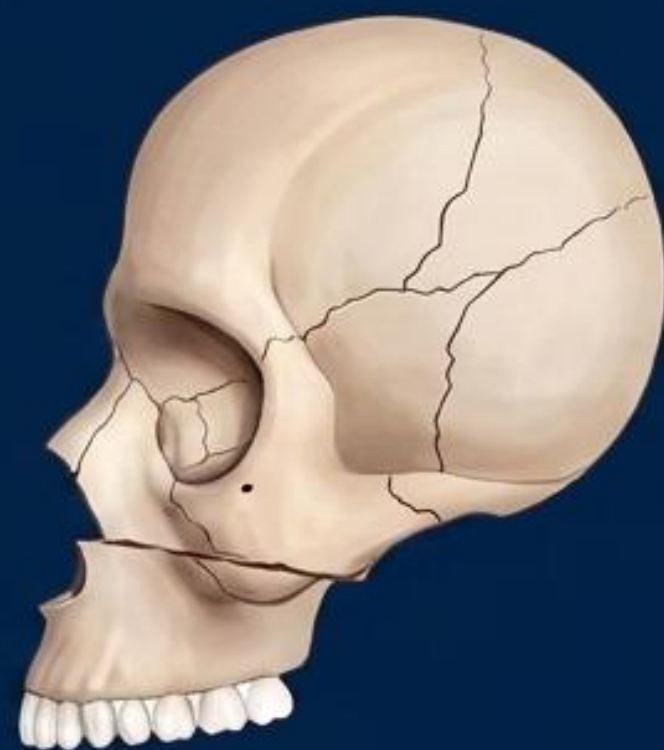Retrusive mandible: position with mandible backward.

Protrusive mandible: position with mandible forward.

Lateral: position to the side;

Mesiolateral: is toward the center of the face.

Distolateral: is toward the outside of the face.



Orthognathic Surgery

Surgical manipulation of facial skeleton to restore :

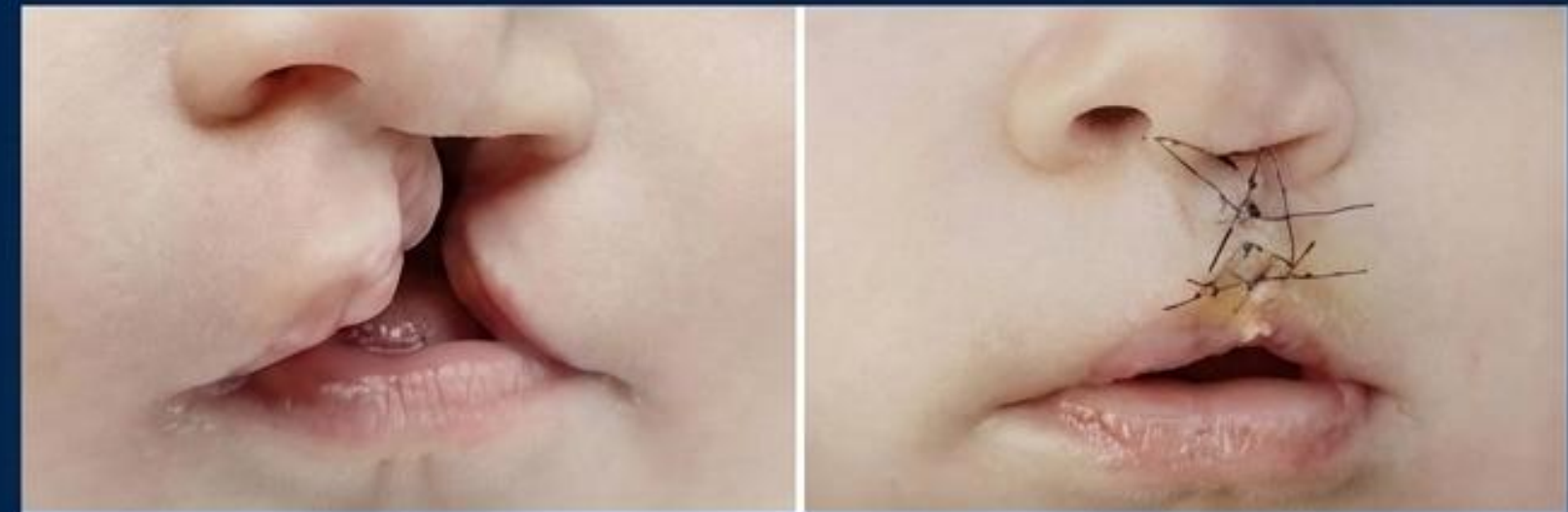- 1- Facial aesthetics**
- 2- Proper Function to affected patients**

And is Performed in cooperation with orthodontic involvement in planning and treatment.

Lip and palate malformations:

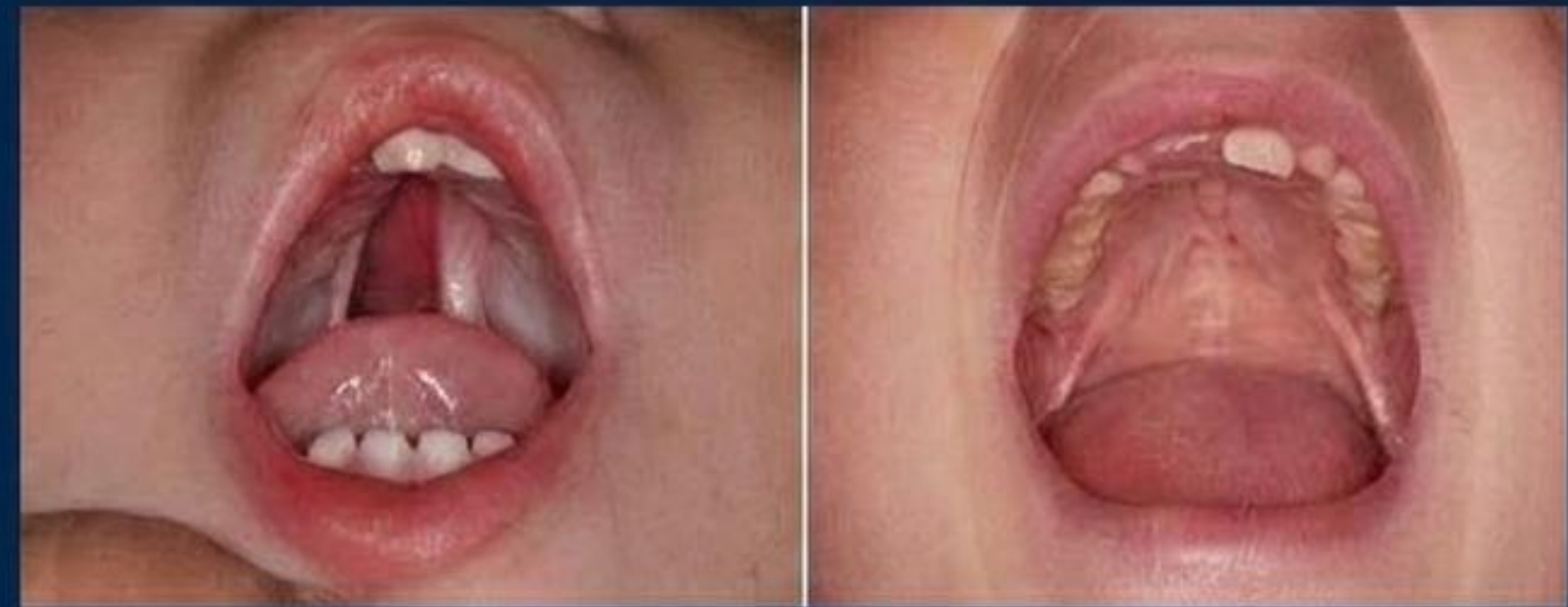Cleft lip: tissue fissure or incomplete juncture of maxillary lip tissues; a congenital defect.

Cleft lip repair: tissue closing and repair of the opening lip tissue gap.



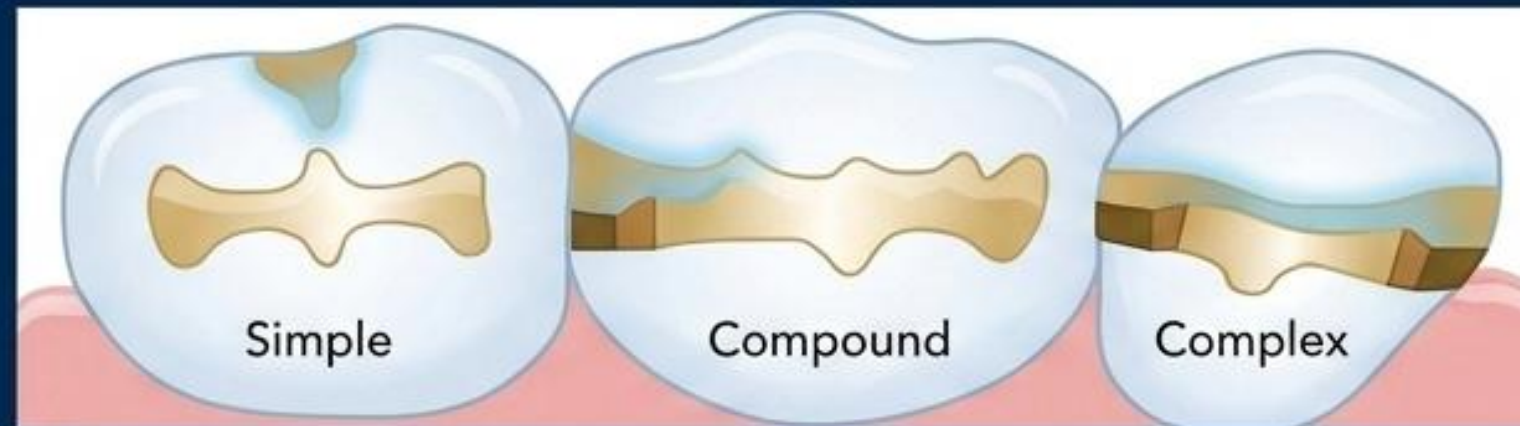
Cleft Palate

- **congenital fissure in the roof of the mouth with an opening into the nasal cavity;**
- **May be :**
- **Unilateral (One-Sided)**
- **Bilateral (two-sided)**
- **Complete**
- **Incomplete**

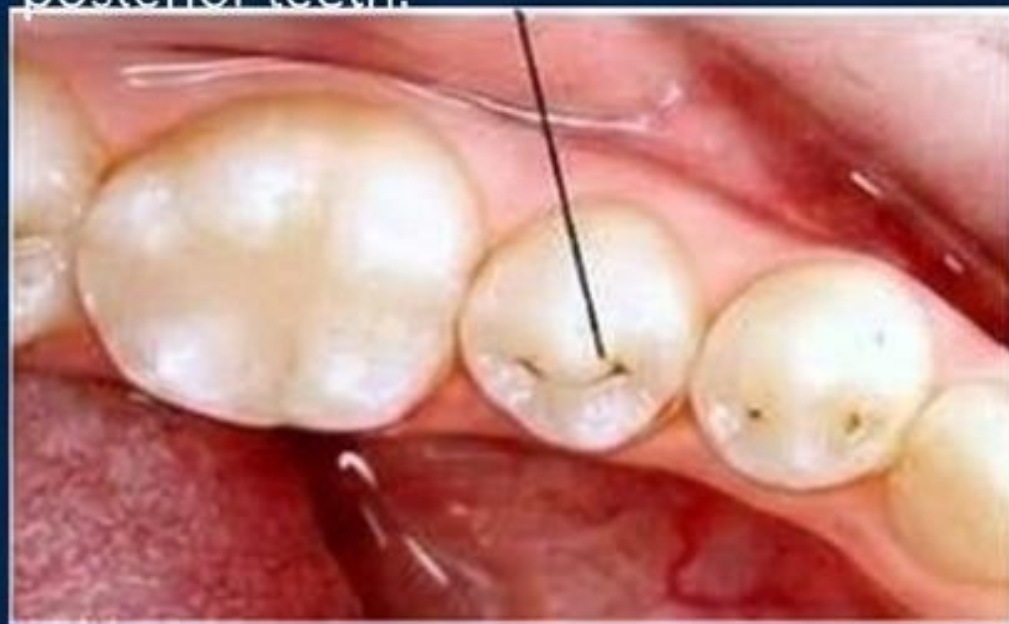

Cleft palate repair:
closing of palatine tissues combined
with orthodontic treatment.

Dental Caries



Simple cavity: decay involving one surface of the tooth, usually on the occlusal surface, the lingual surface of maxillary incisors, or fissured buccal or lingual surfaces of the mandibular posterior teeth.



Compound cavity: decay involving two surfaces of a tooth, usually charted as mesio-occlusal (MO), disto-occlusal (DO), or any other two surfaces.

Complex cavity: decay involving more than two surfaces, usually charted as mesioocclusodistal (MOD) or any other three or more surfaces.

Dental Terminology

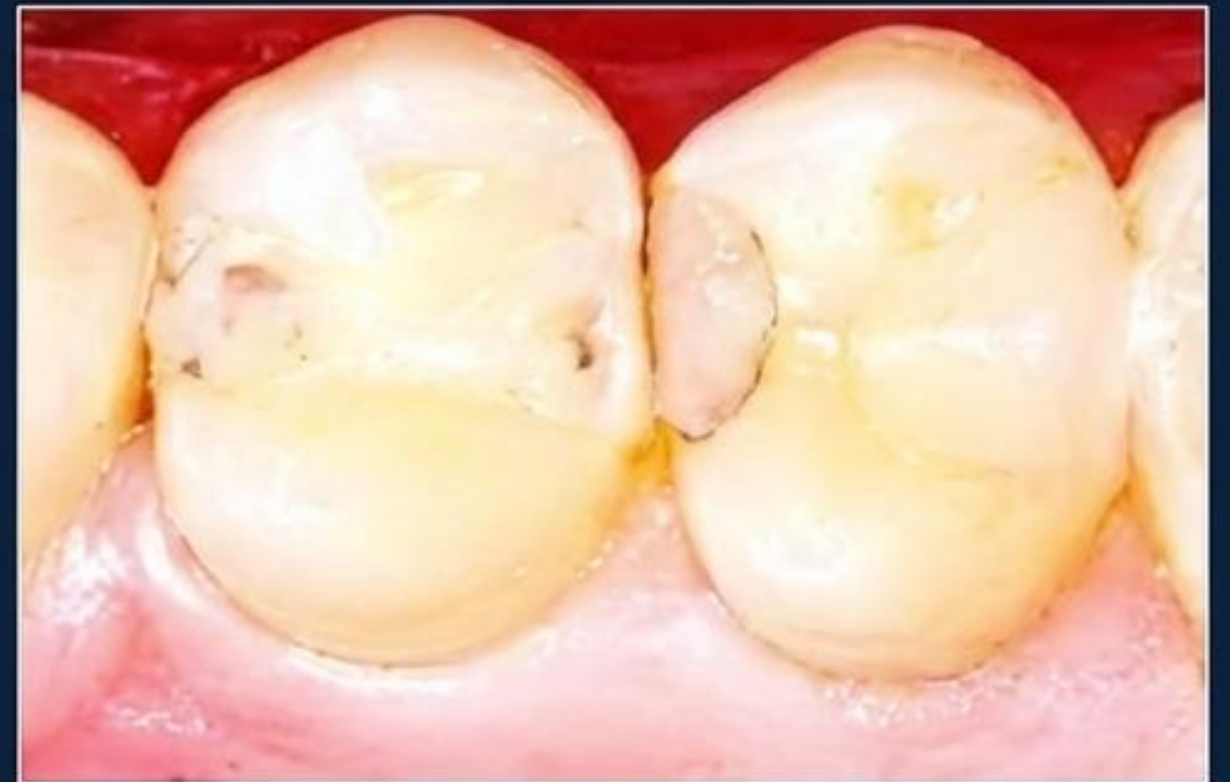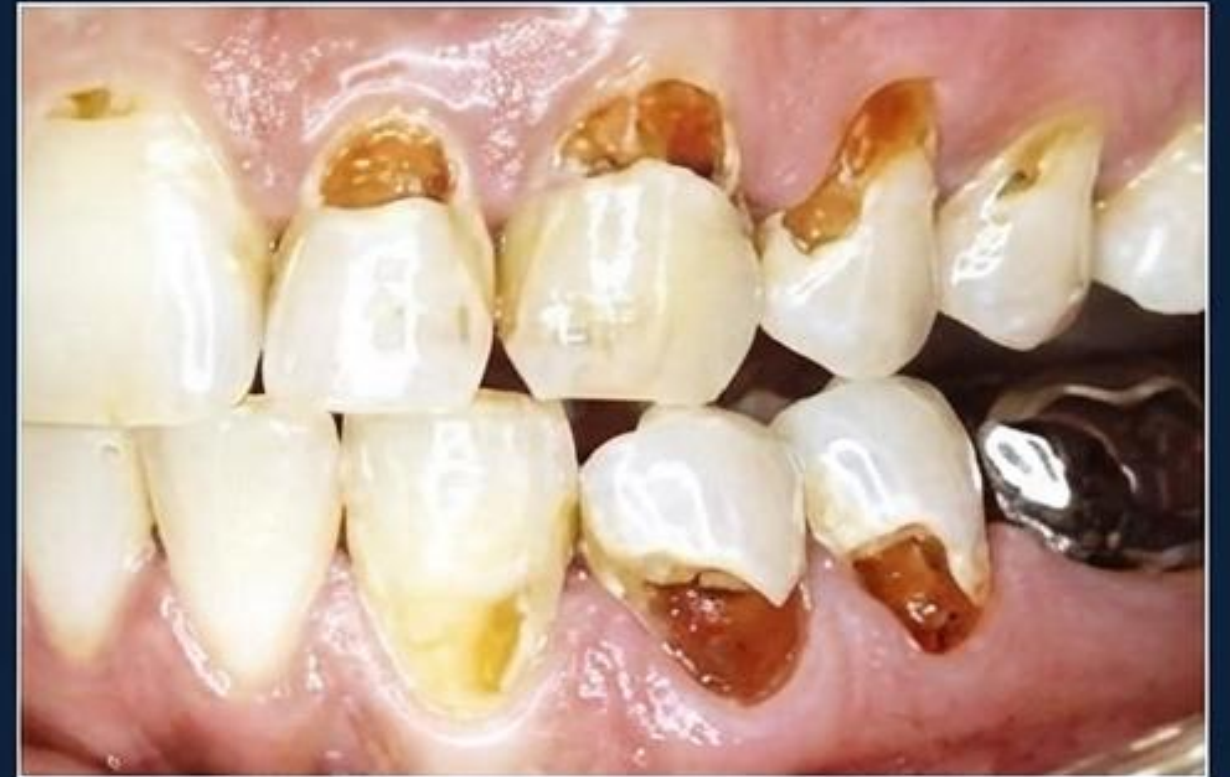Dental caries is also known as decay or carious lesions.

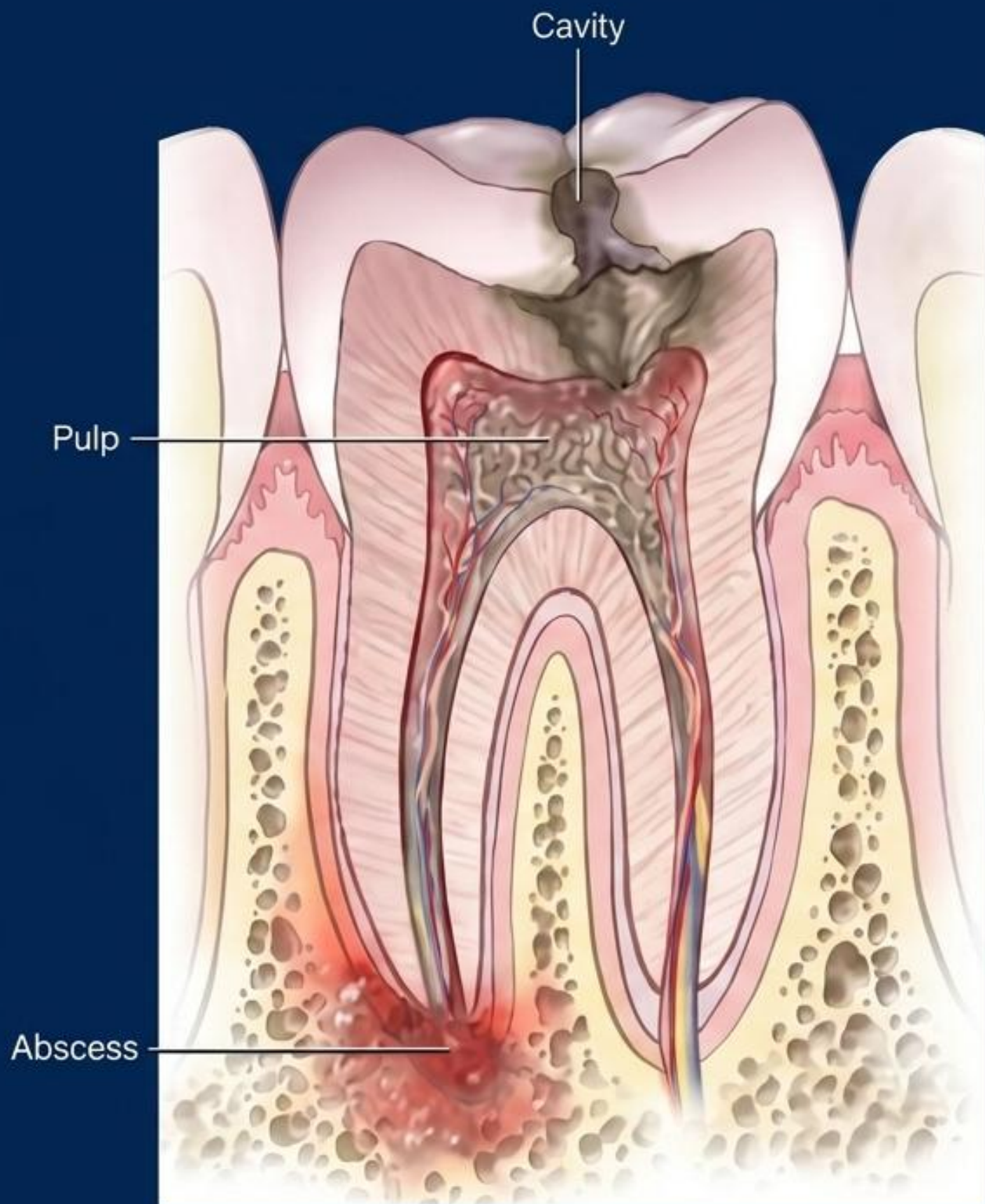
Arrested caries: decay showing no progressive tendency.

Incipient caries: beginning decay.

Rampant caries: widespread or growing decay.

Recurrent caries: decay occurring under or near repaired margins of tooth restorations.






Periapical abscess


A periapical (around the tooth apex) abscess is also called a gum abscess. An abscess results from the necrosis (death) of pulp tissues.

The three stages of pulp irritation are:

Hyperemia (over, blood), an increase in blood and lymph vessels, as a result of irritation from decay.



Pulpalgia (Pulp=inner tooth tissue, algia = pain), tooth pain or toothache resulting from irritation and infection in the pulp chamber.



Pulpitis (inflammation of the pulp), inflammation and swelling of pulp tissue, leading to necrosis or death of the pulp.