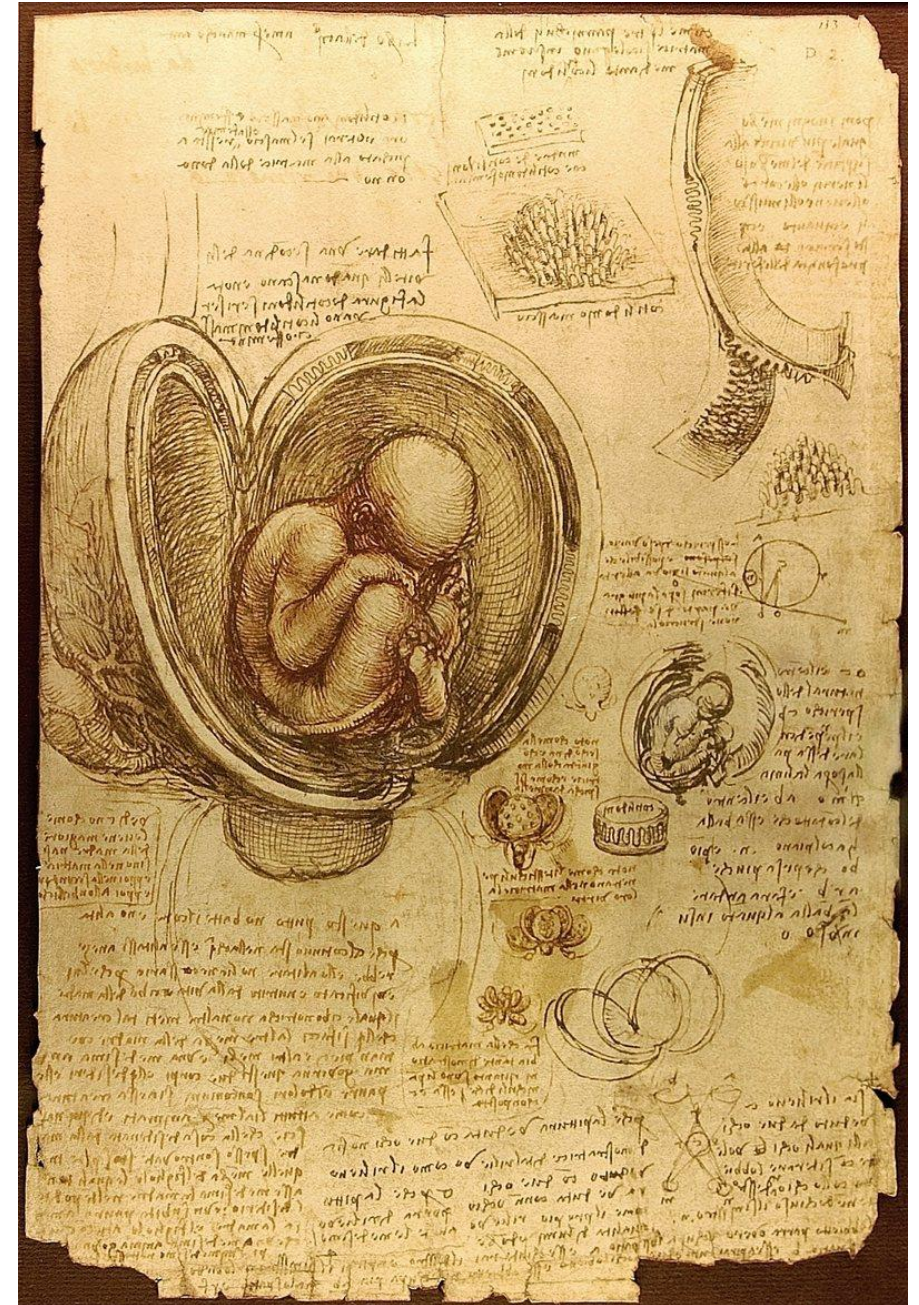
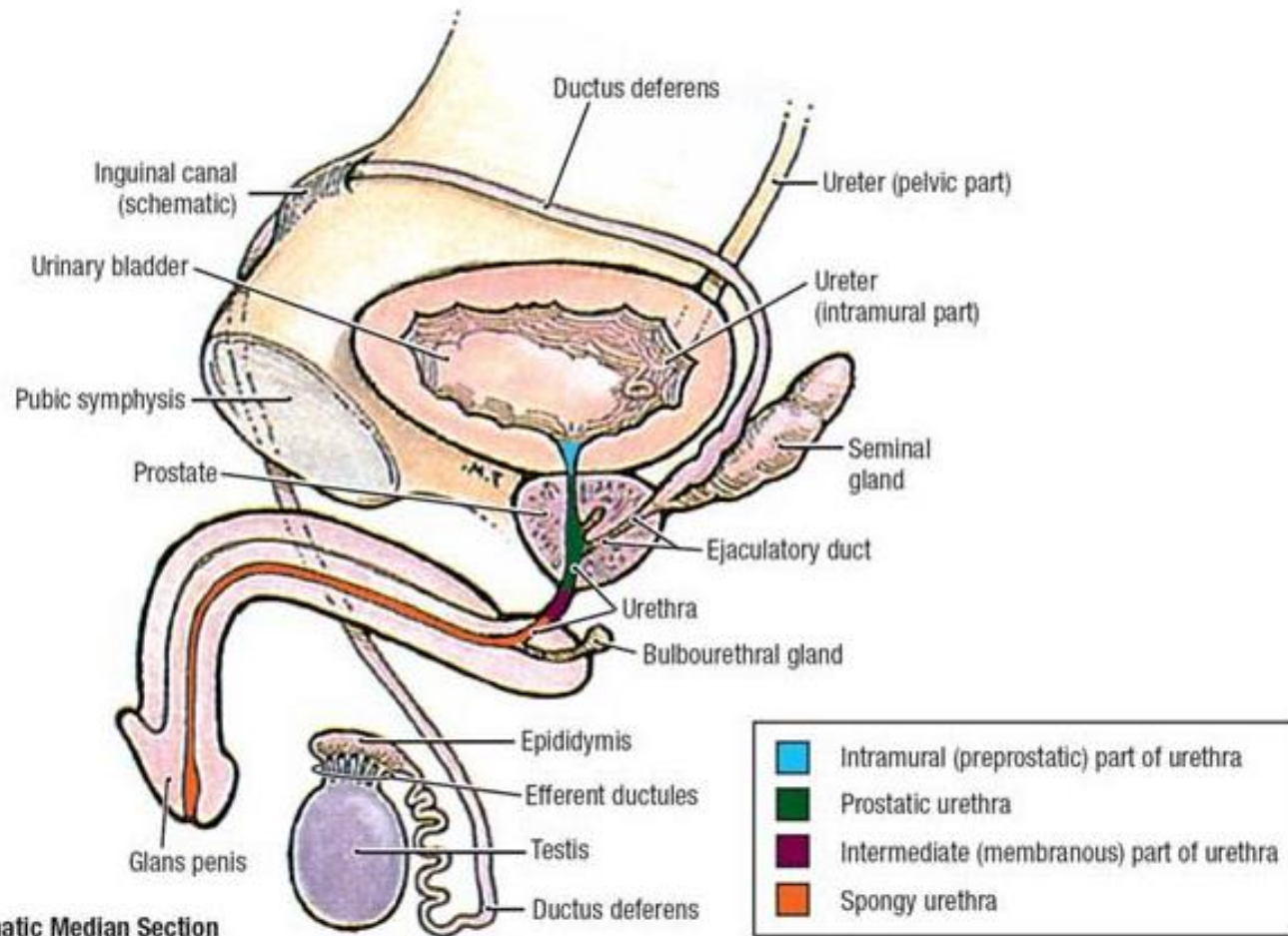


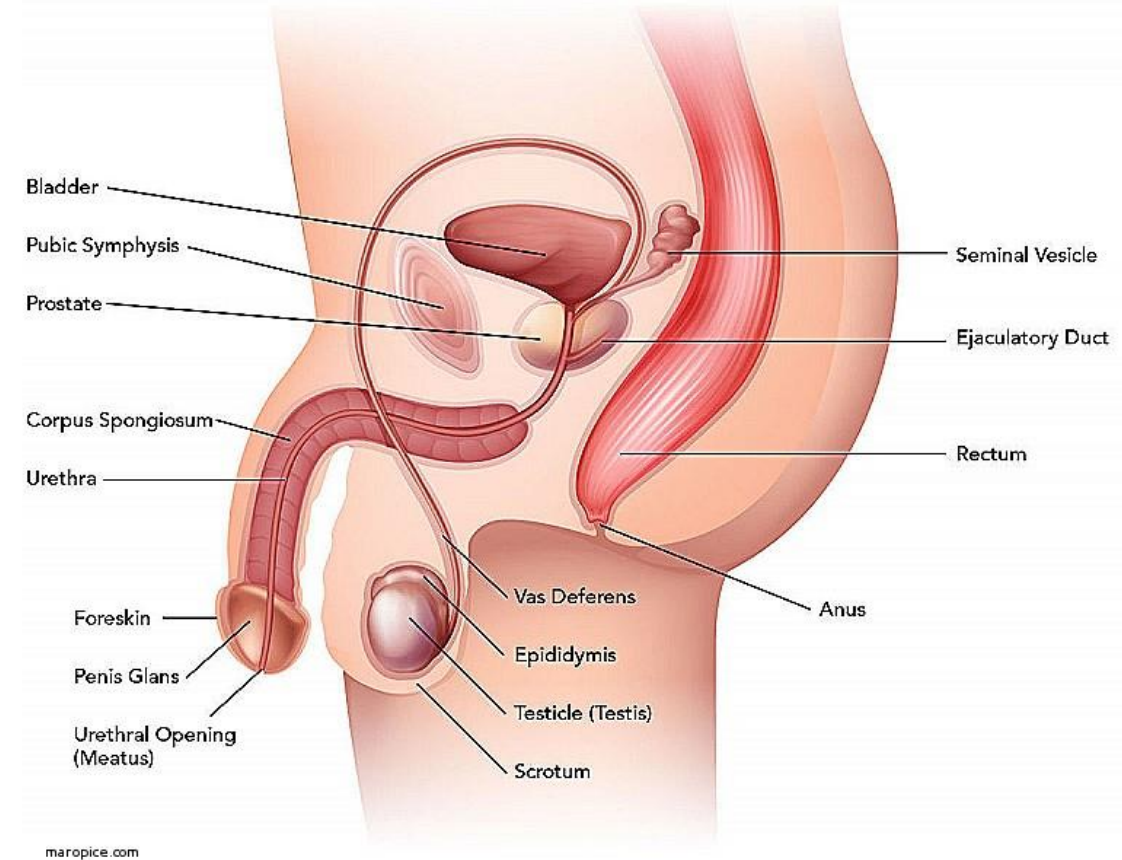
The Male & Female Genital Systems

Dr. Ali Mohsin

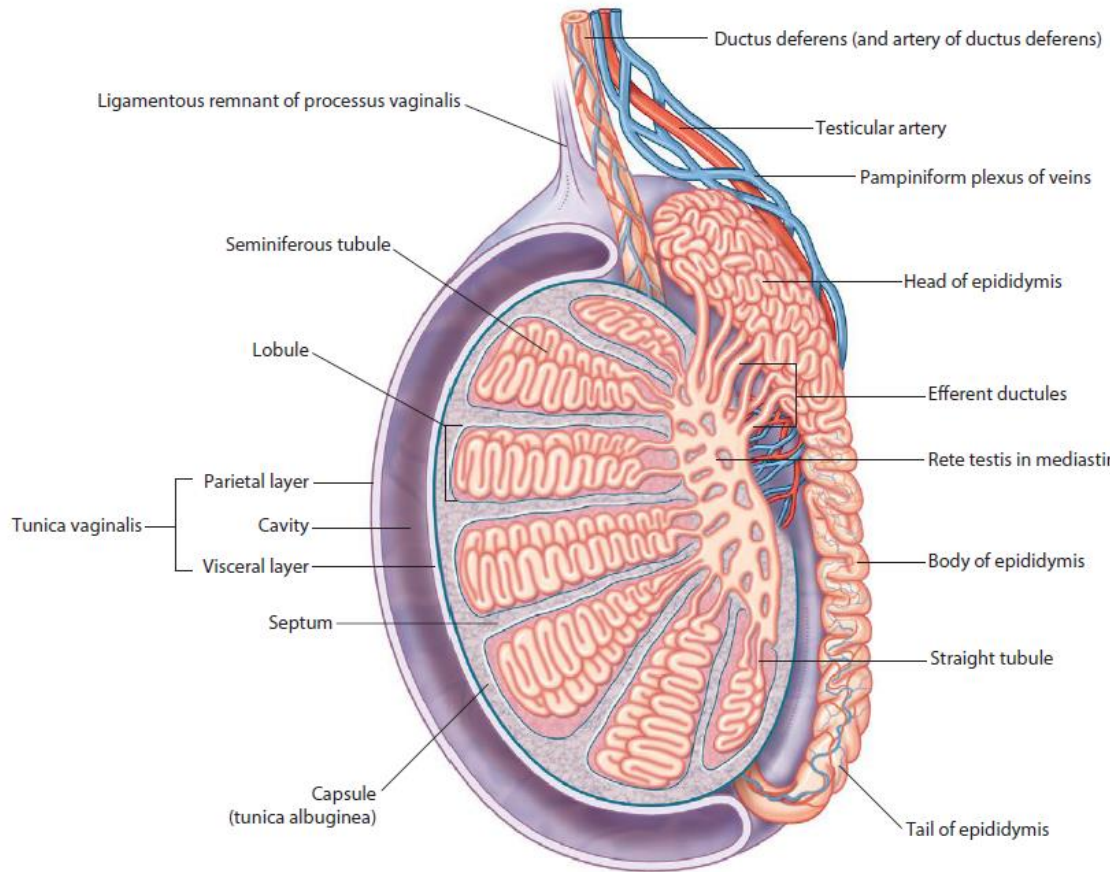




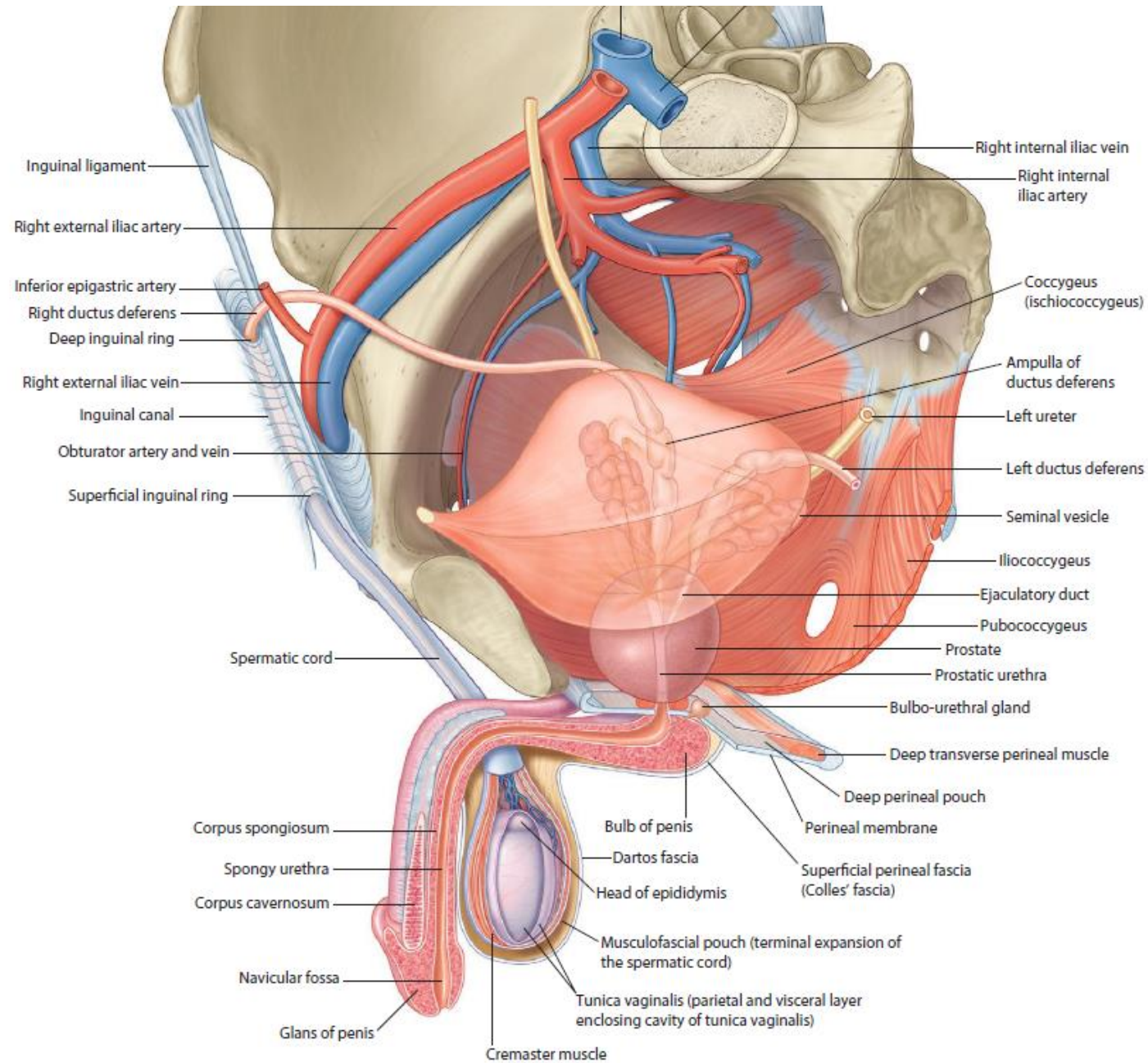
Male Reproductive System



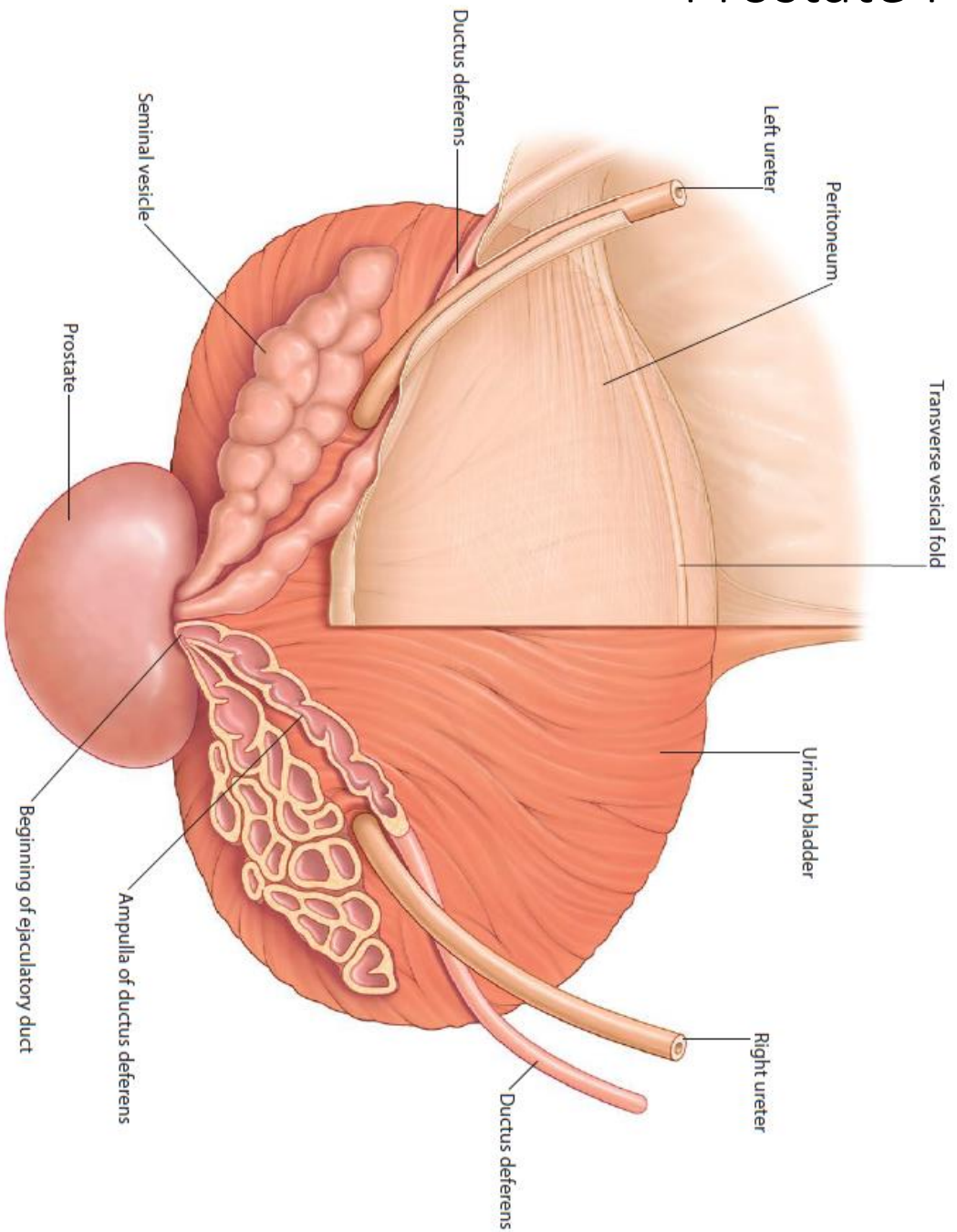
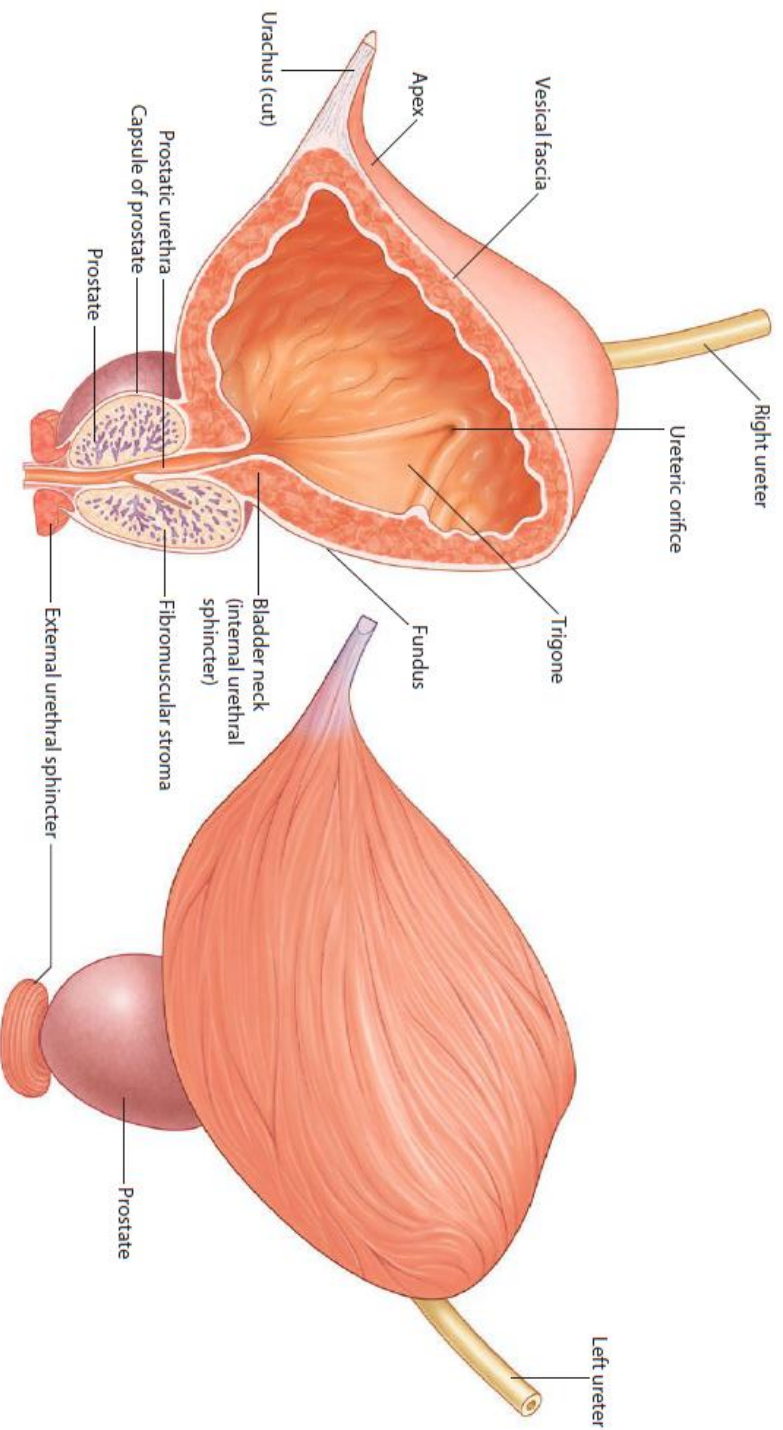
Position of the male organs in the

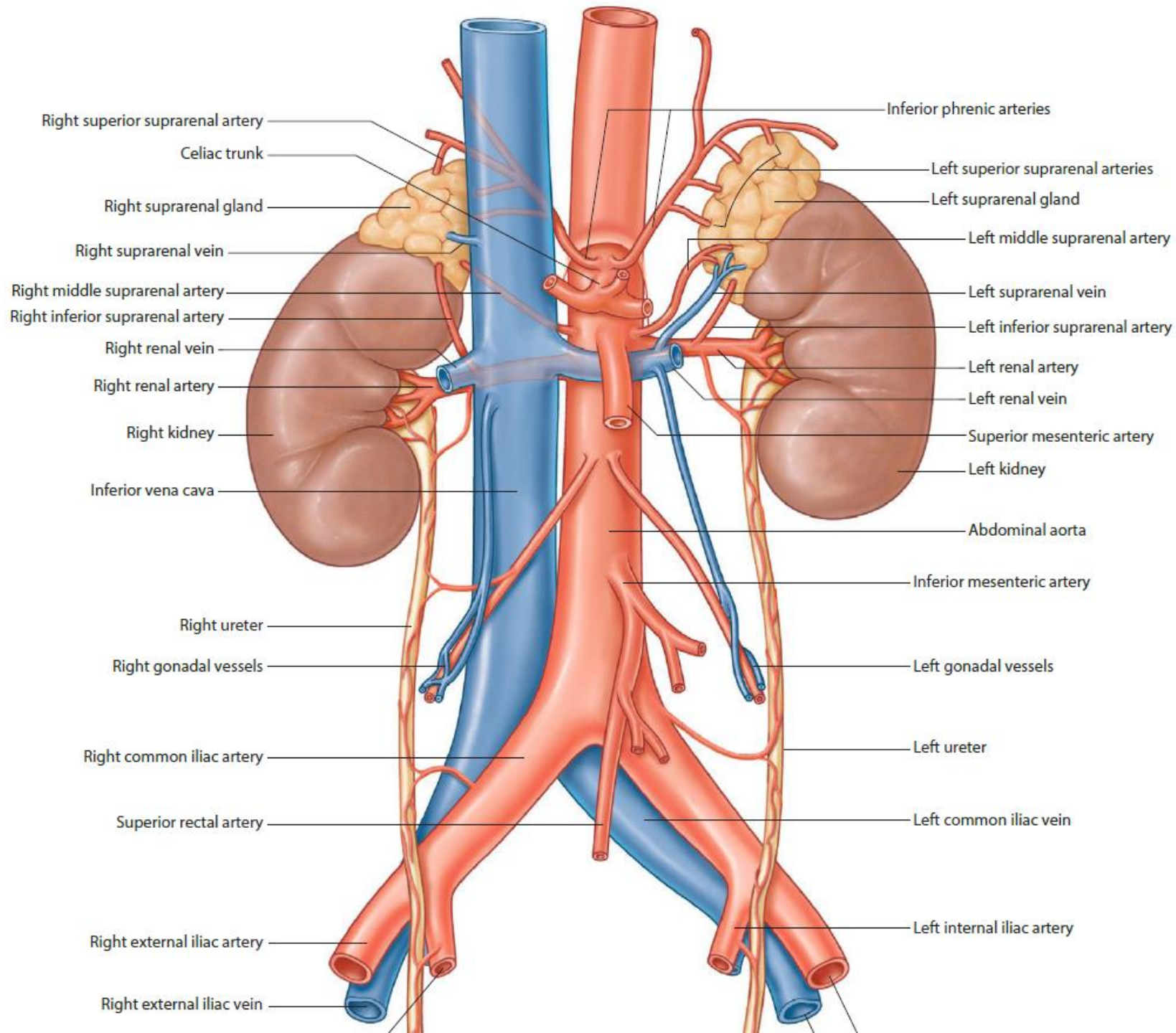


Testis and surrounding structures

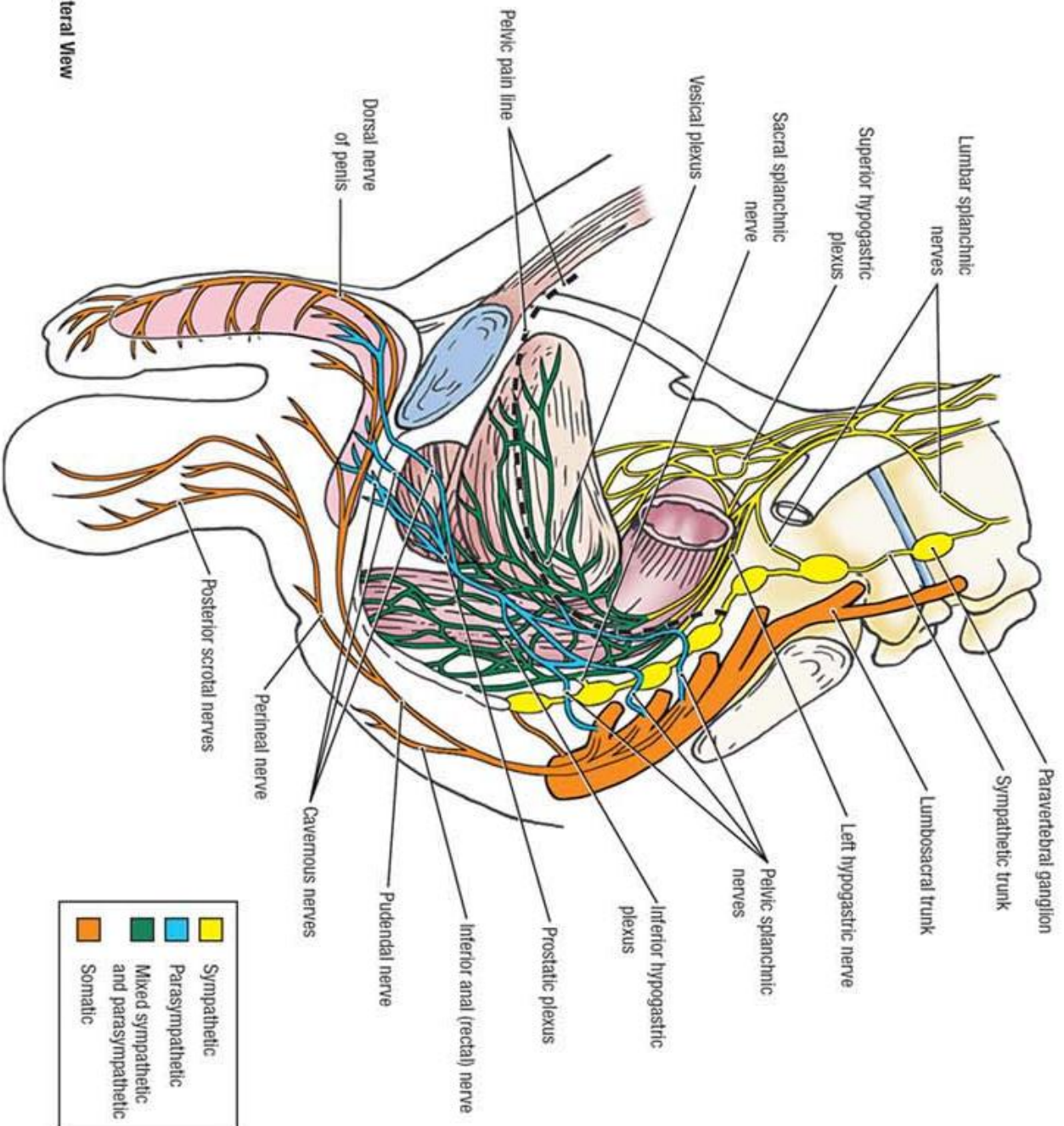
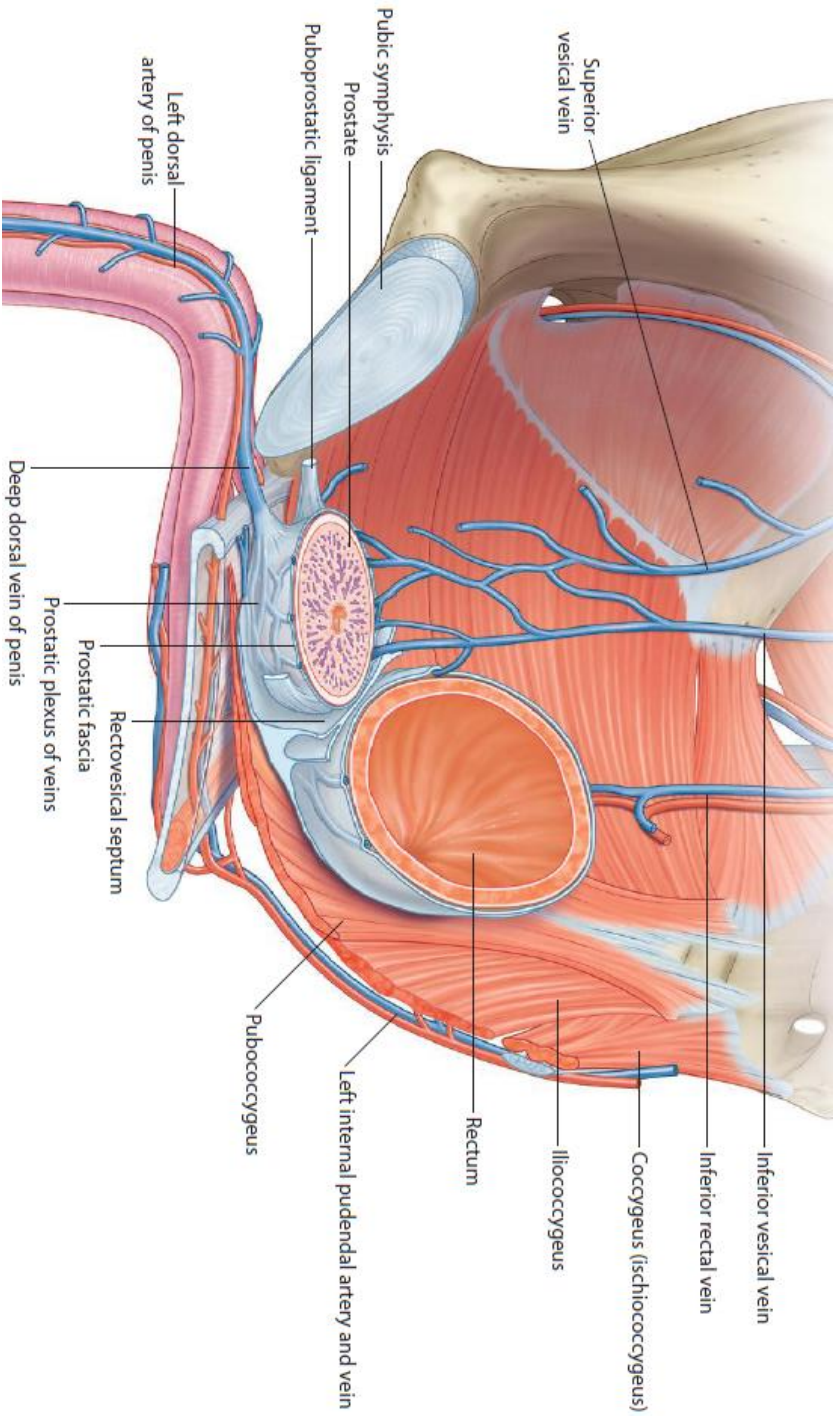


Prostate Position





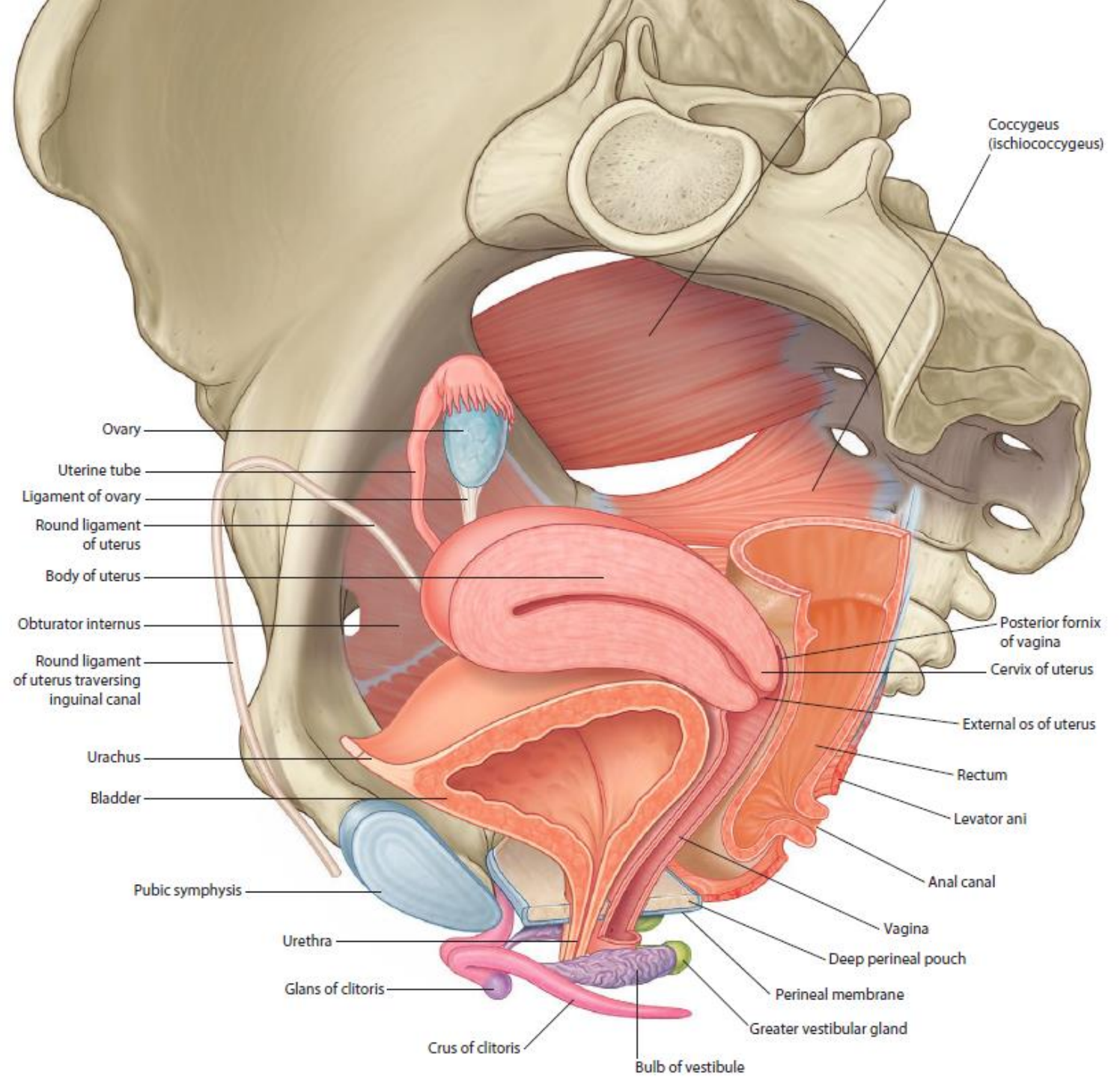
Blood & Nerve Supply

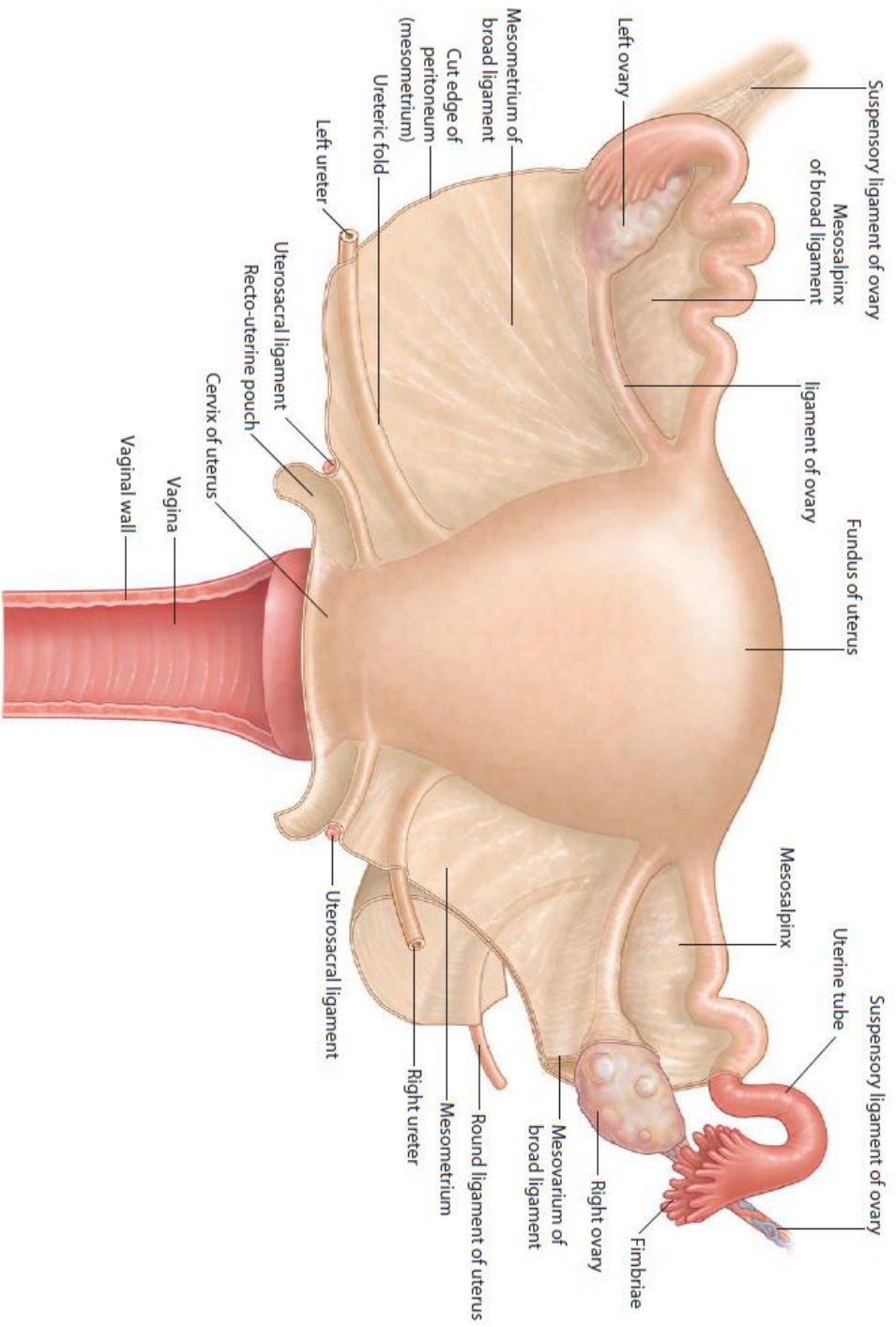


■	Sympathetic
■	Parasympathetic
■	Mixed sympathetic and parasympathetic
■	Somatic

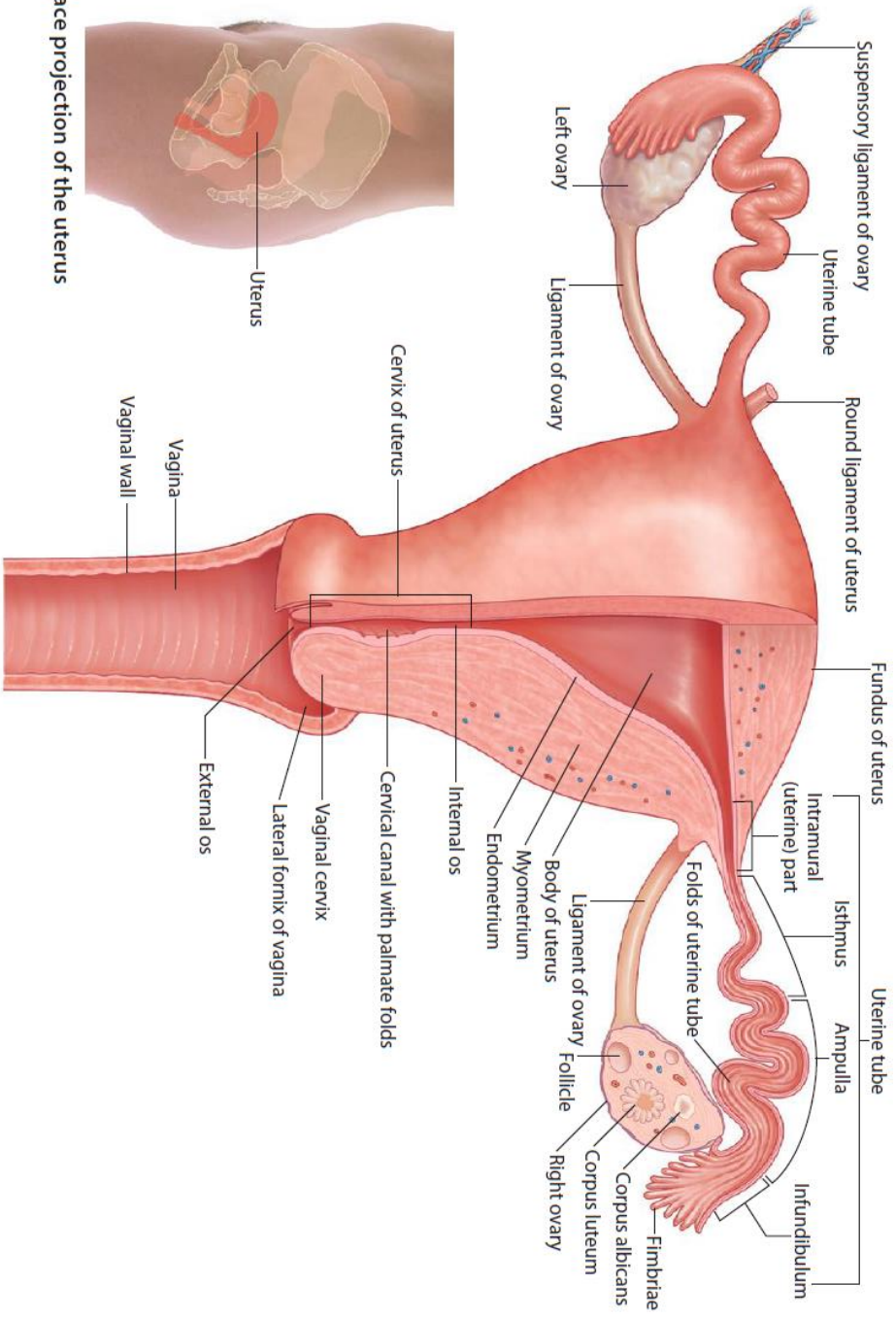
B. Lateral View

Position of the female organs in the pelvis

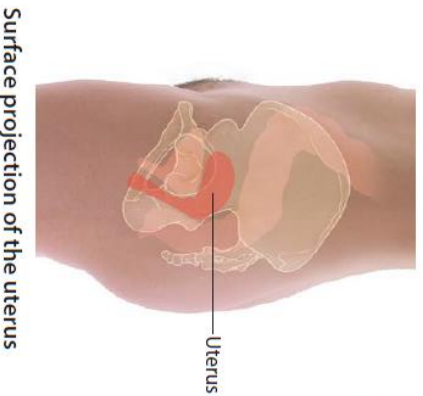




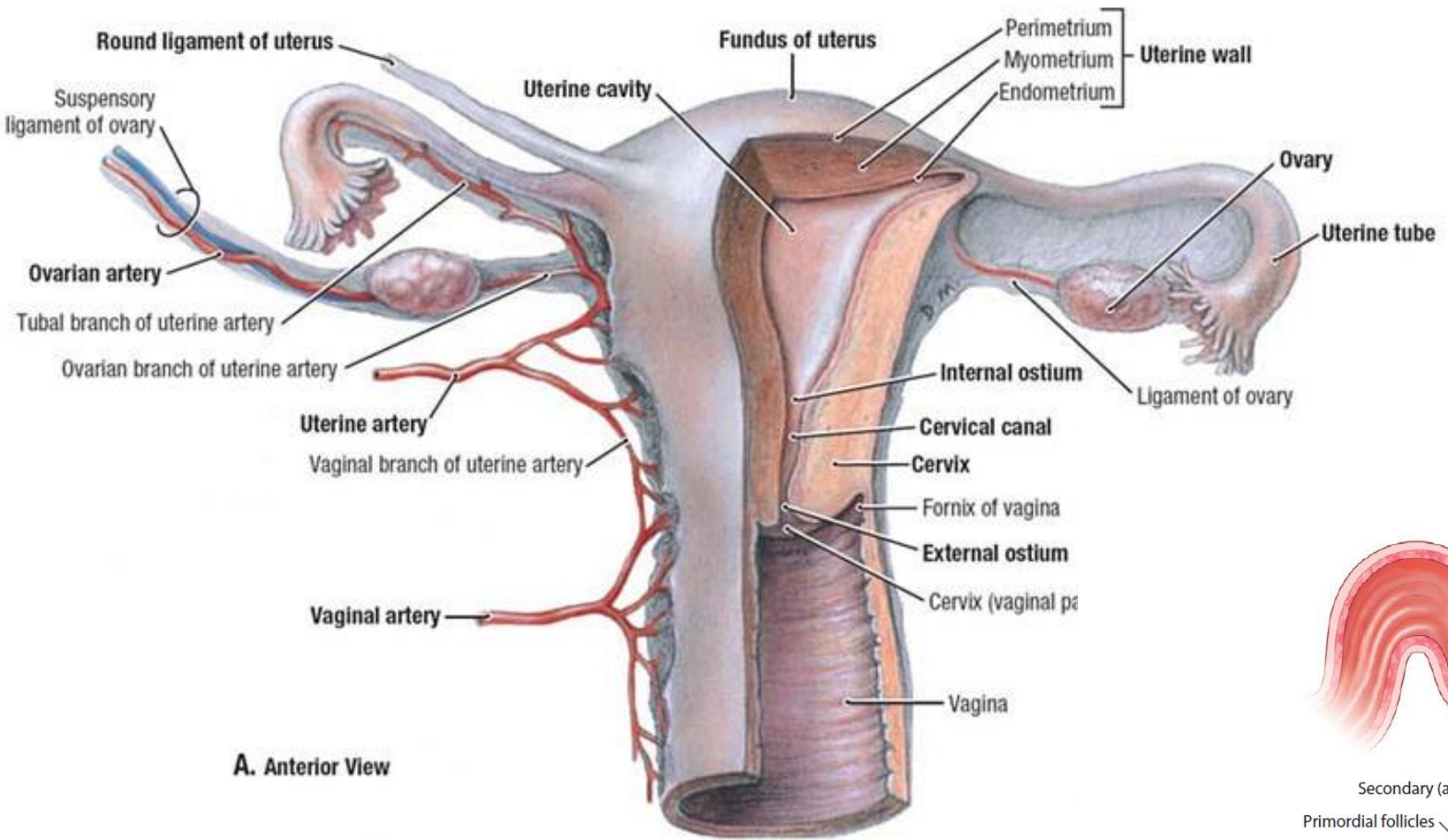
Uterus and broad ligament (posterior view)



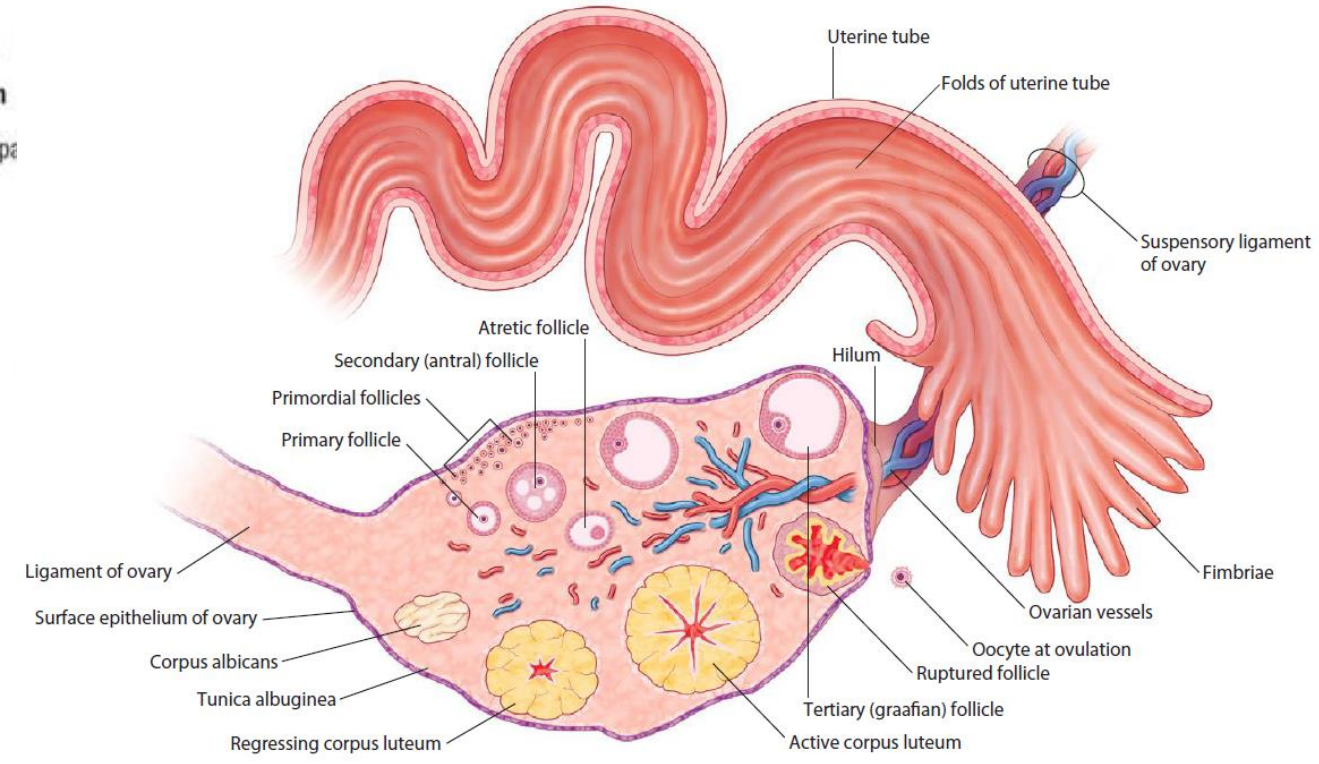
Structure of the uterus and ovaries (posterior view)



Surface projection of the uterus



A. Anterior View



Structure of the uterine tube and ovary (posterior view)

