



GENERAL INTRODUCTION TO ANATOMY

Assis.lecturer. Shaimaaa imad

THE ANATOMY

- is the study of the structure of the body and the relationship of its constituent parts to each other.
- All description of the human body is based on what is called anatomical position (the person is standing erect, with the upper limbs by the sides and the face and palms of the hands are directed forward). The various parts of the body are then described in relation to certain imaginary planes: -



1. **Median- sagittal plane**: is imaginary vertical plane passing through the center of the body, dividing it into equal right and left halves
2. **Para median plane**: is a plane situated to one or the other side of the median sagittal plane and parallel to it
3. **Coronal plane**: are imaginary vertical plane at right angle to the median plane

A structure situated nearer to the median plane of the body than another is said to be medial to the other. Similarly, a structure that lies further away from the median plane than another is said to be lateral to the other.

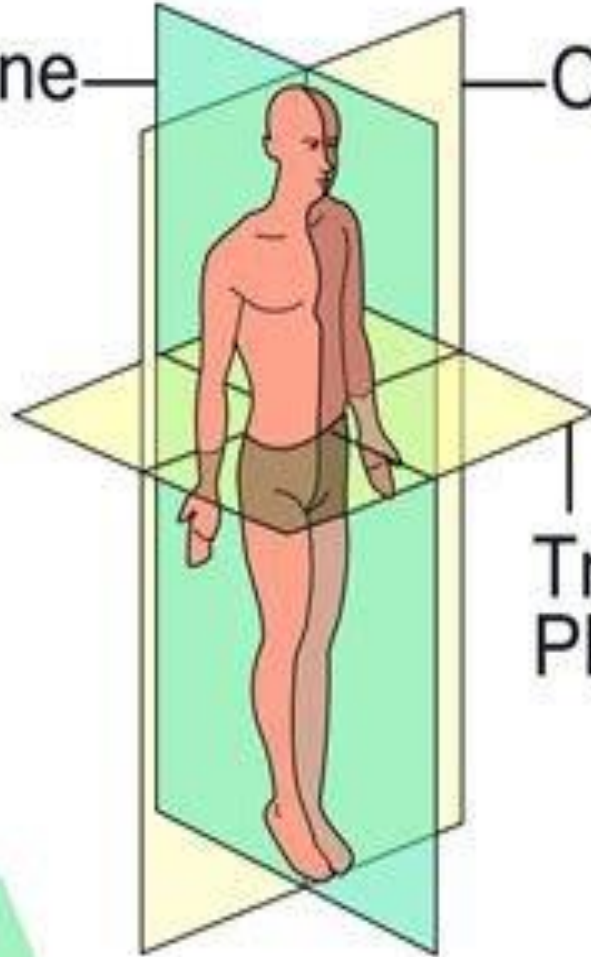
4. **Horizontal or transverse plane**: are imaginary transverse planes at right angle to both median and coronal planes

The **term anterior and posterior** are used to indicate the front and back of the body respectively, in describing the hand, the term palmer and dorsal surfaces are used in place of anterior and posterior, and in describing the foot, the term planter and dorsal surfaces are used in place of lower and upper surfaces



Sagittal Plane

Coronal Plane



Transverse Plane

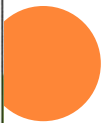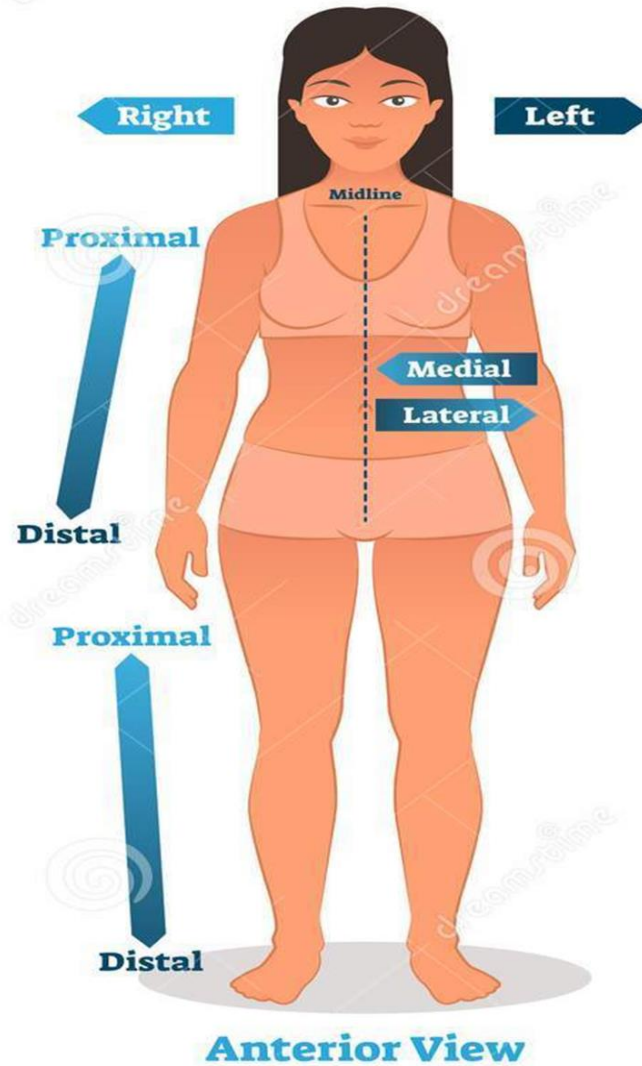
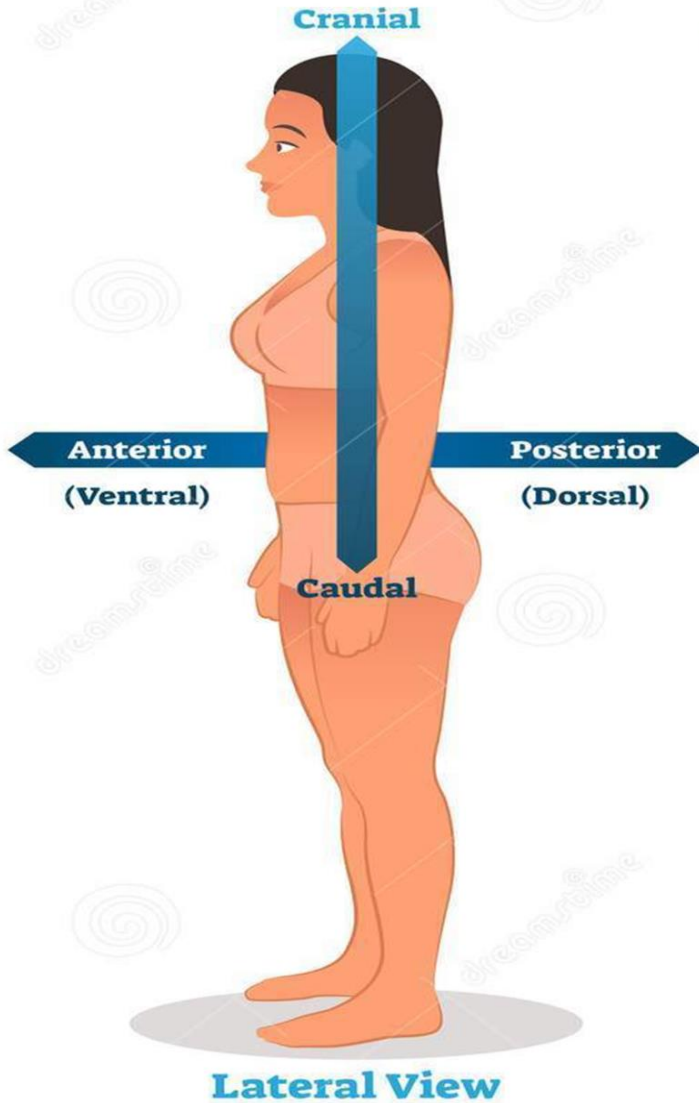
Body Planes



- ❖ The **term proximal and distal** describe the relative distance from the roots of the limbs, for e.g. the arm is proximal to the forearm and the hand is distal to the forearm.
- ❖ The **term superficial and deep** denote levels relative the distance of the structure from the surface of the body.
- ❖ The **term internal and external** are used to describe the relative distance of the structure from the center of an organ or cavity for e.g. the internal carotid artery is found inside the cranial cavity and the external carotid artery is found outside the cranial cavity.
- ❖ The **term supine position** denoted the body is laying on the back and the **prone position** is lying face downward



ANATOMICAL POSITION




TERMS RELATED TO MOVEMENT: -

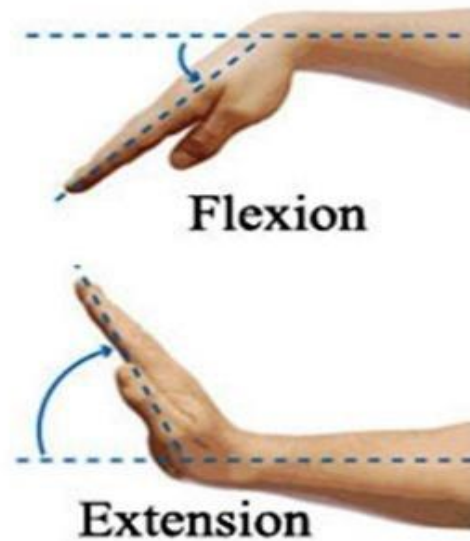
The joint is the site where two or more bones come together.

- **Flexion:** is a movement that take place in a sagittal plane e.g. flexion of the elbow joint
- **Extension:** mean straightening the joint & usually takes place in posterior direction.
- **Abduction:** is a movement of the limb away from the midline of the body in the coronal surface
- **Adduction:** is a movement of the limb toward from the midline of the body in the coronal plane .
- **Rotation:** is the term applied to the movement of a part of the body around its long axis.

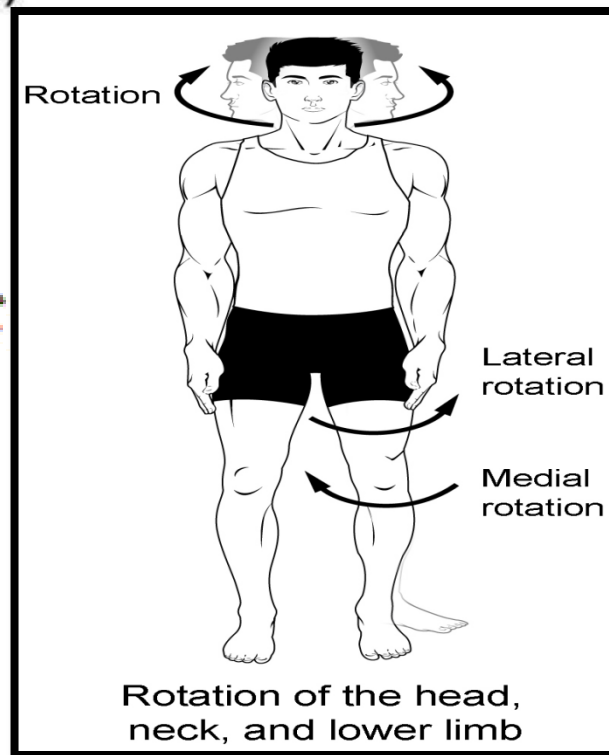
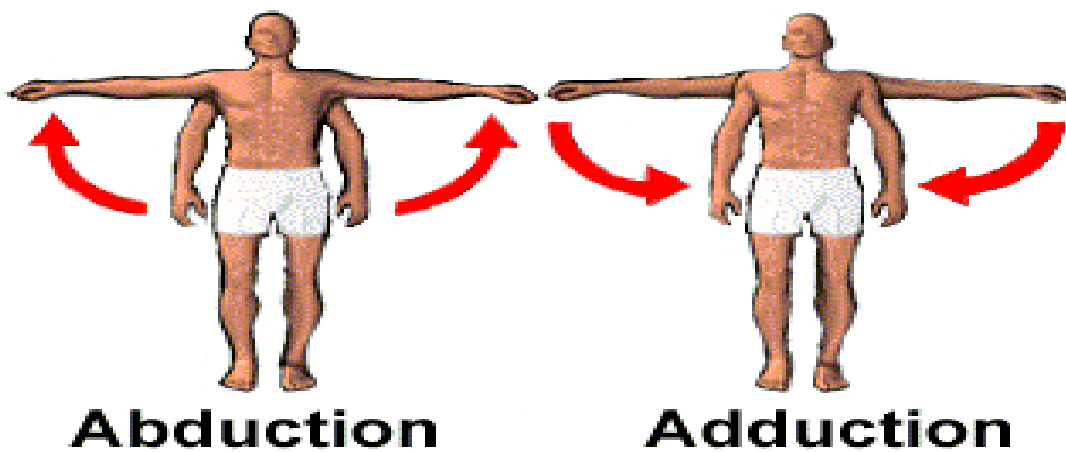




(a)



(b)



SOME BASIC ANATOMICAL STRUCTURES:

- Skin:
- The skin is divided into two parts:
 - ▪ The superficial (epidermis)
 - ▪ The deep (dermis)
- **Fasciae:** - The fasciae of the body may be divided into two types, the superficial and the deep fasciae. They lie between the skin and the underlying muscles and bones.



JOINTS

- Joints is the site where two or more bones come together, whether or not there is movement between them. Joints are classified according to the tissue that lie between the bones:-
 - 1. fibrous joint.
 - 2. cartilaginous joint.
 - 3. synovial j
- 1 joints may be classified according to the Arrangement of the articular surfaces & the type of movement that are possible:



Plane joint

- ----- the appose articular surfaces are flat or almost flat & thus permits the bone to slide upon one another .eg. sternoclavicular

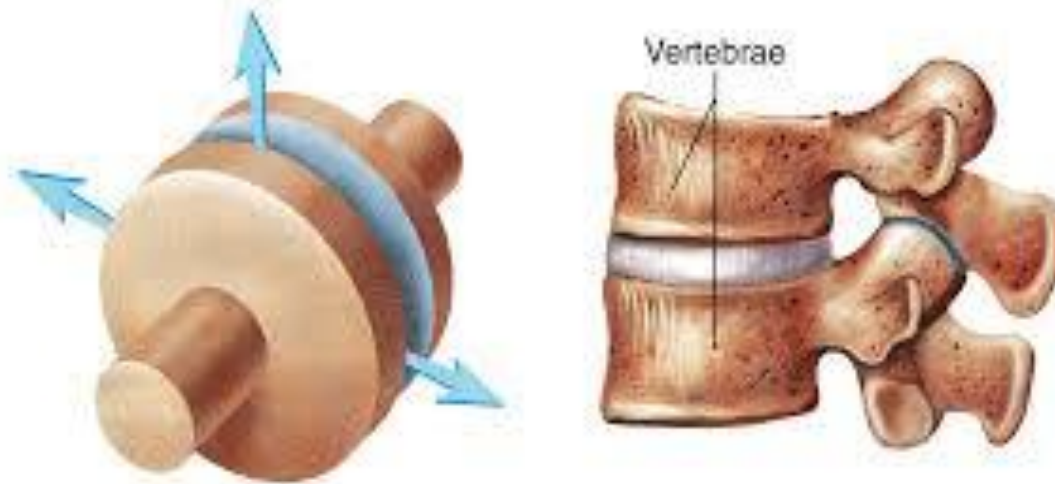
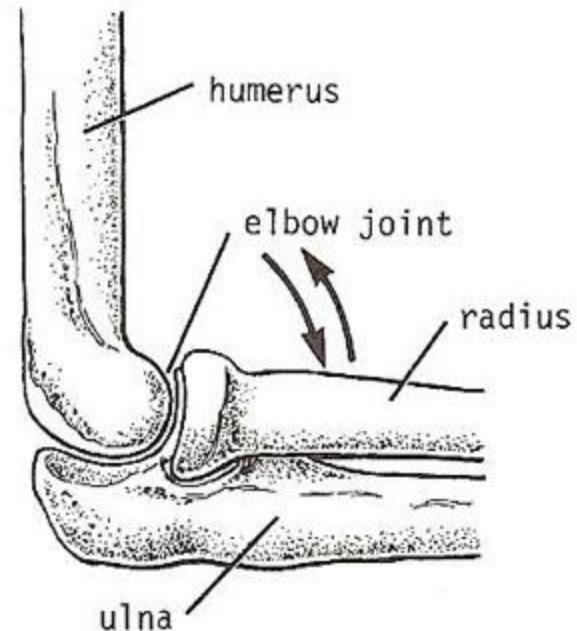
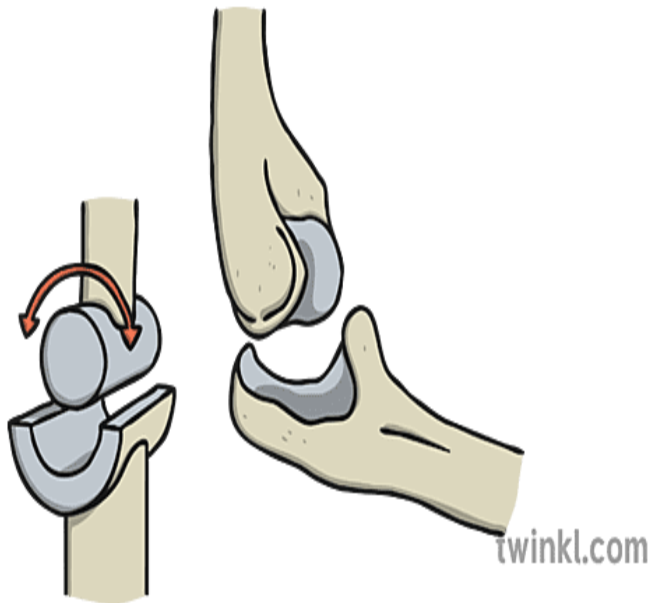


FIGURE 8.8 Plane Joint



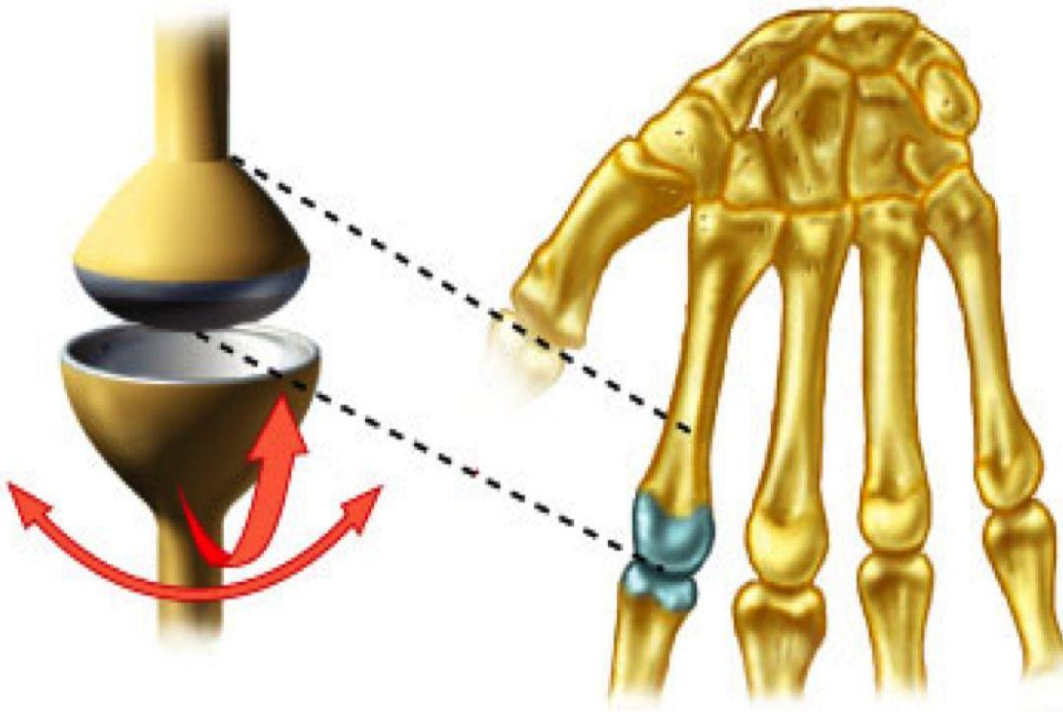
Hinge joint

- ----- these j. resembling a hinge on a door. So that flexion& extension movement are possible. eg. elbow, knee & ankle



Condyloid joint

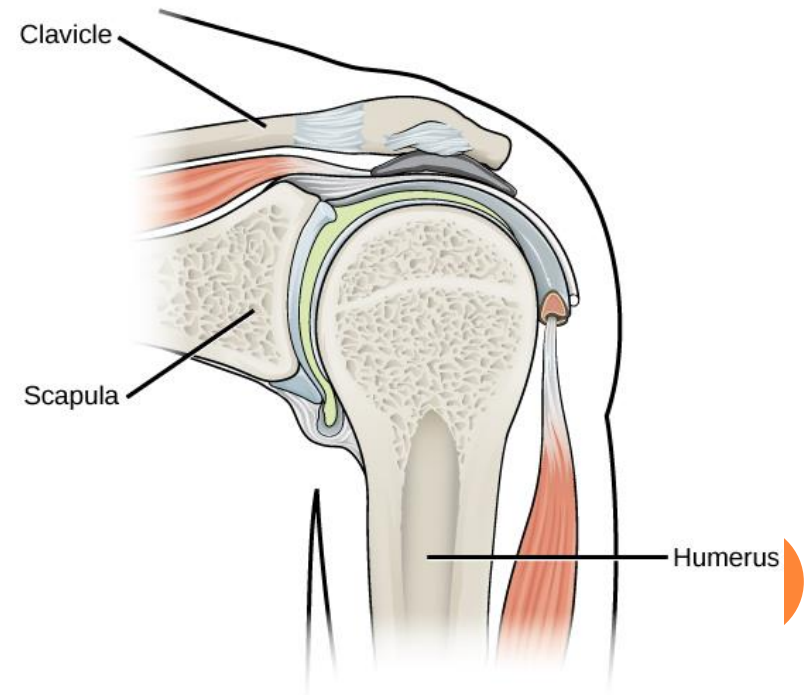
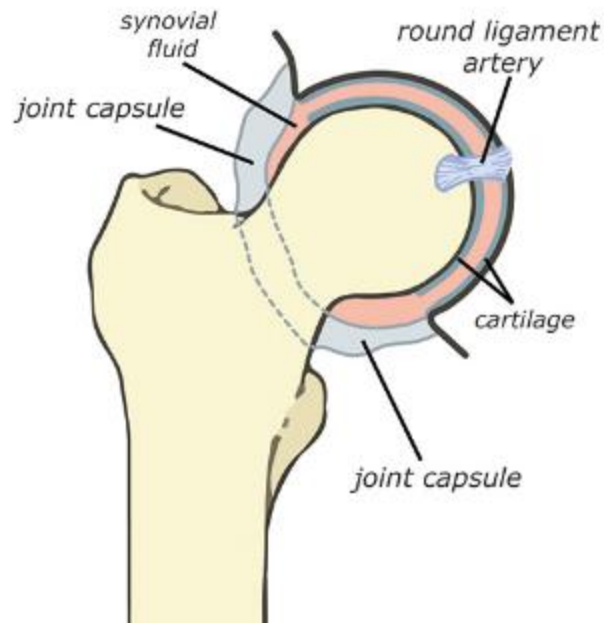
- ----- these j. have 2 distinct convex surfaces that articulate with 2 concave surfaces. The movement of flexion, extension, abduction & adduction are possible together with a small amount of rotation. eg. The metacarpophalangeal j.



Ball & socket joint

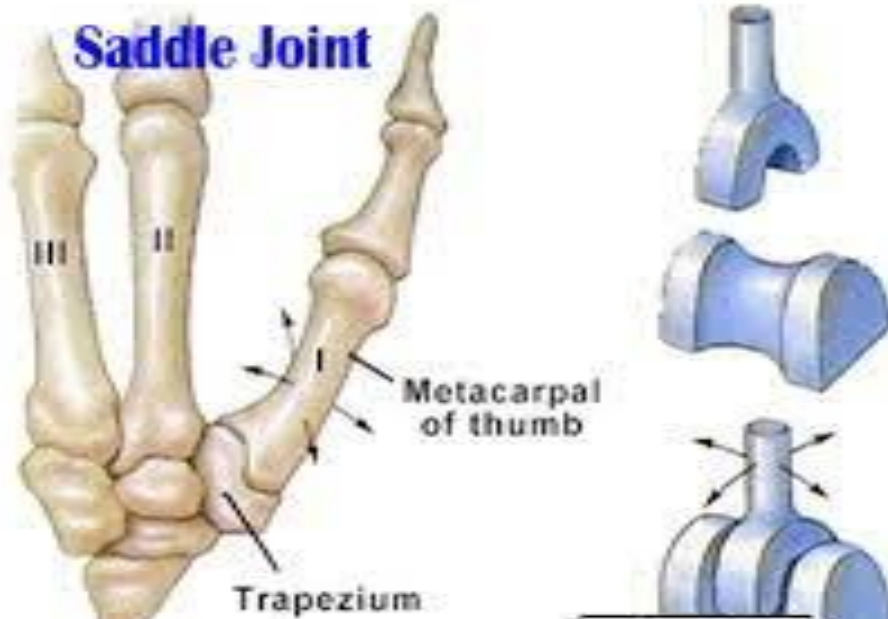
- ----- in these j. a ball shaped head of one bone fit into a socket like concavity of another. This arrangement permit very free movement including flexion, extension, abduction ,adduction, medial rotation, lateral rotation & circumduction. eg. The shoulder & hip j

Hip joint capsule



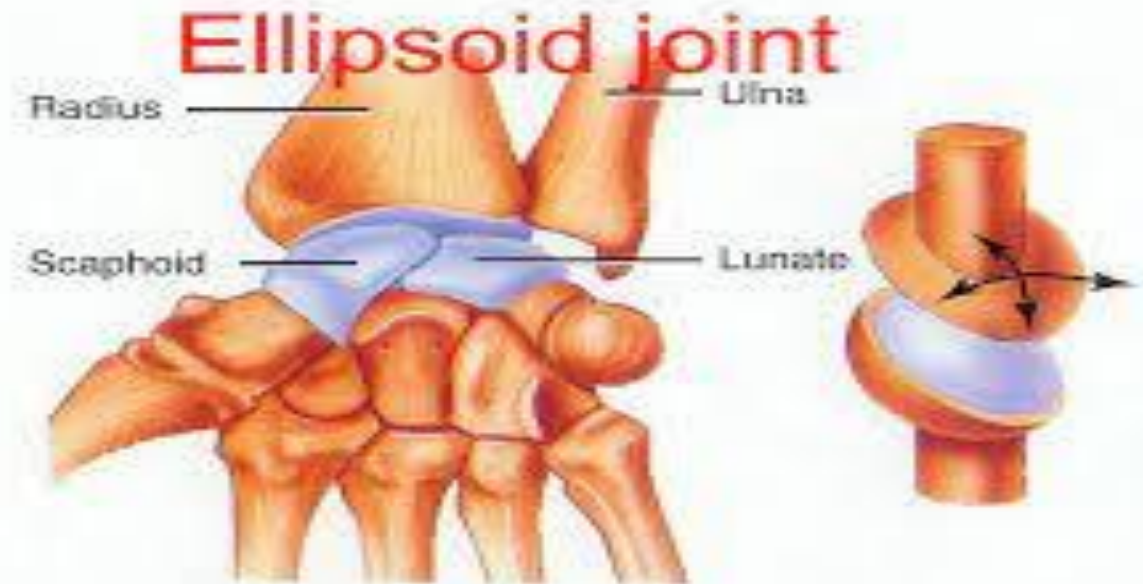
SADDLE JOINT

- ----- in these j. the articular surfaces are reciprocally concavoconvex & resemble a saddle on a horse's back. These j. permit flexion, extension, abduction, adduction & rotation .eg. carpometacarpal j. of the thumb.



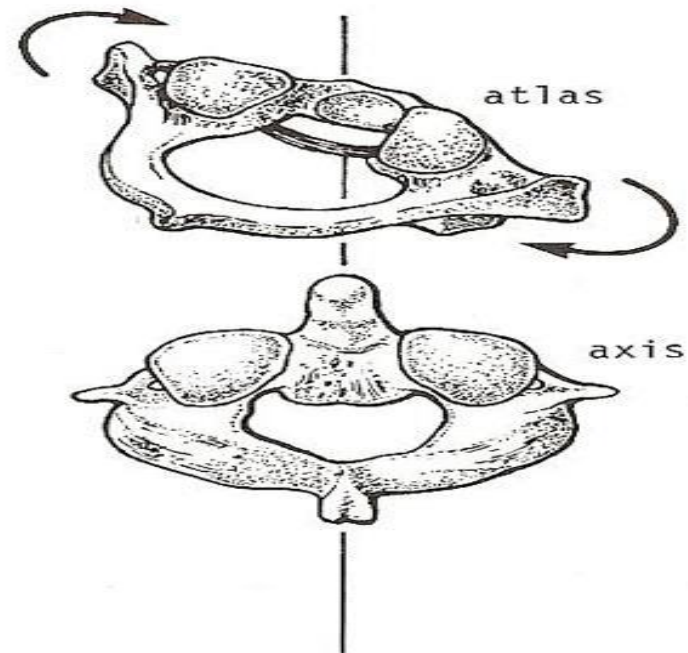
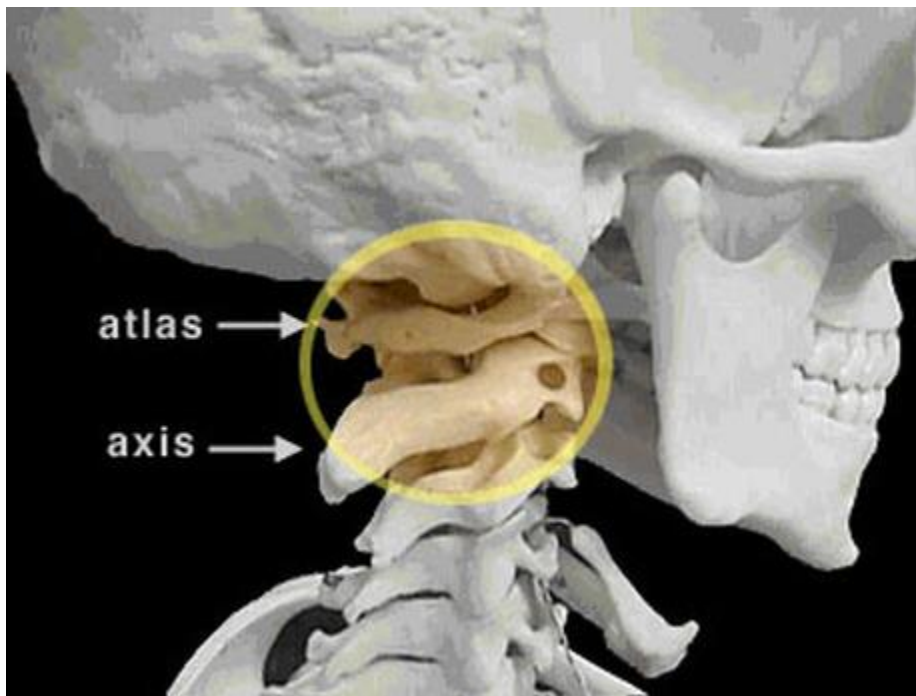
ELLIPSOID JOINT

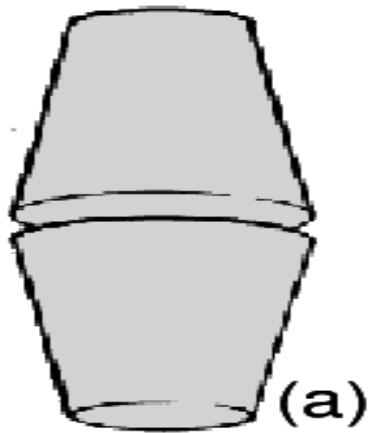
- ----- in these j., there is an elliptical convex articular surface that fits into an elliptical concave articular surface. The movement of flexion, extension, abduction &,adduction can take place, but rotation is impossible. eg. wrist j.



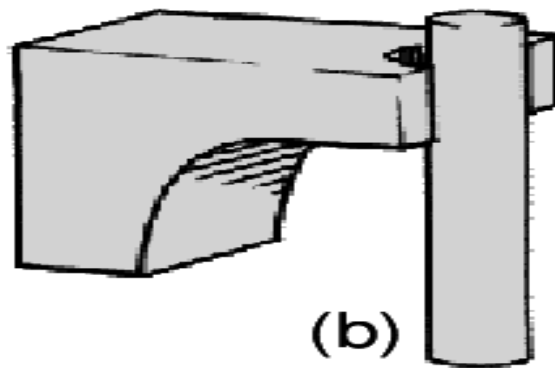
PIVOT JOINT

- ----- in these j. there is a central bony pivot surrounded by a bony-ligamentous ring. Thus rotation is the only movement possible.eg. the atlantoaxial j.

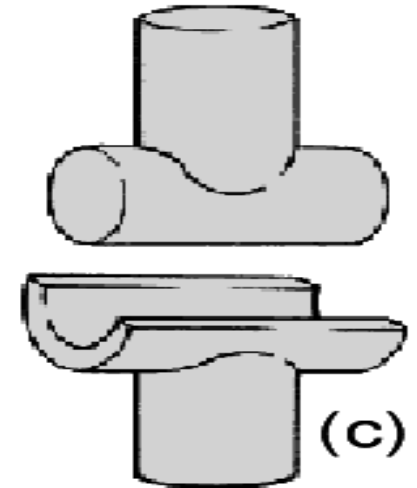




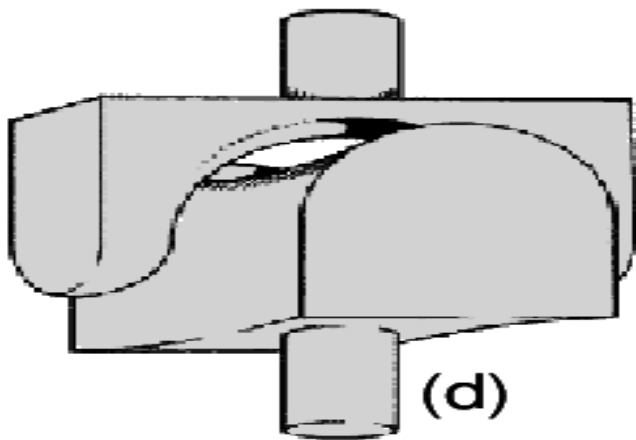
Plane



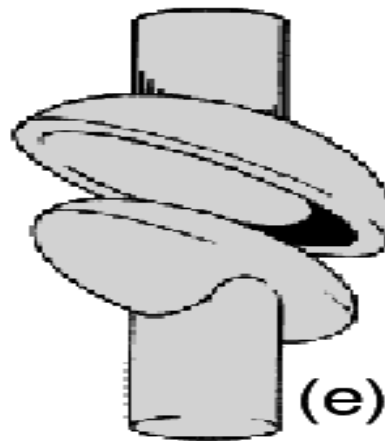
Pivot



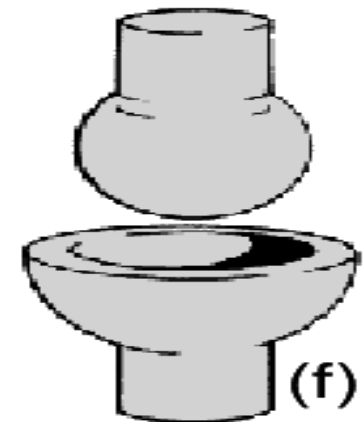
Hinge



Saddle



Ellipsoid



Ball and
Socket

رابط محاضرة توضيحية

- https://youtu.be/0cYal_hitz4histo



Thank You.

