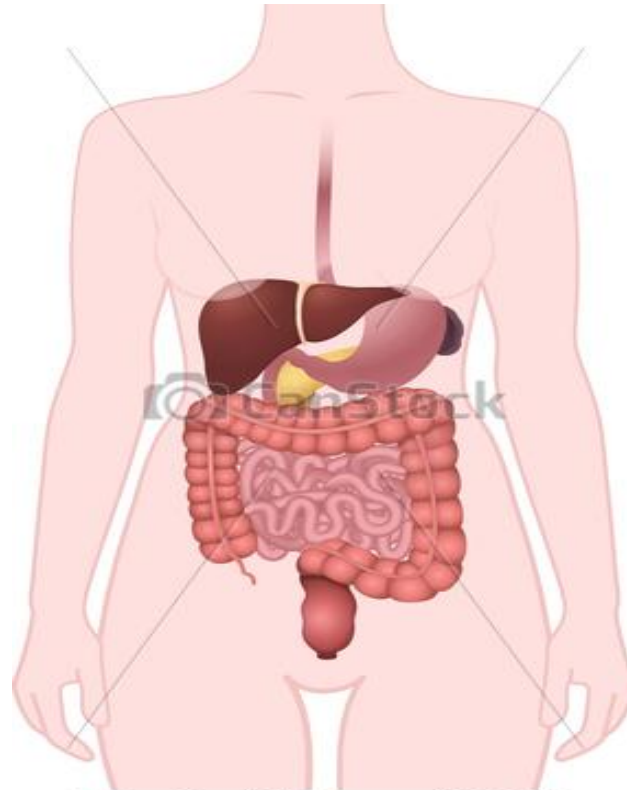


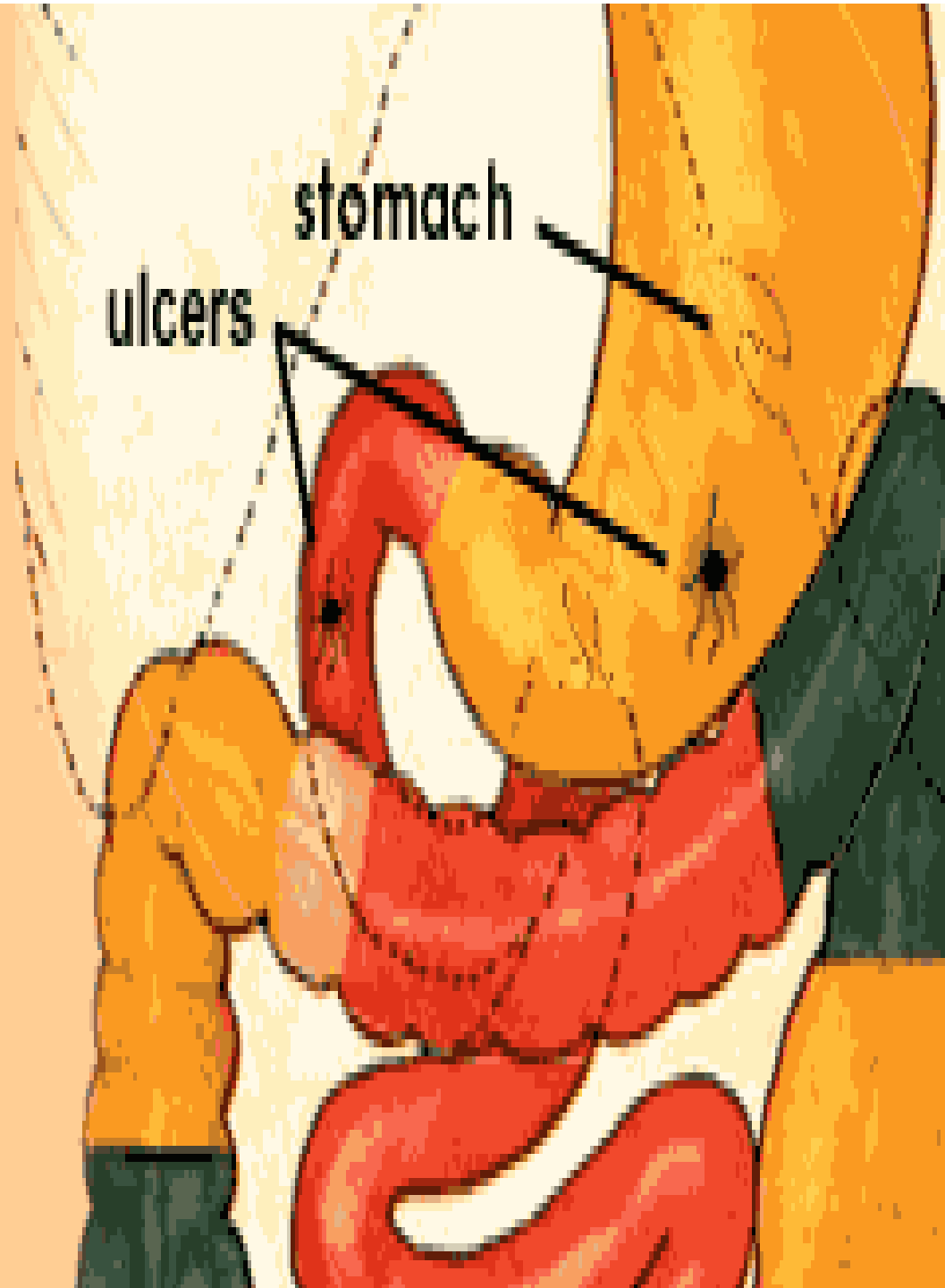
Gastro-Intestinal Tract

Lab 7



© Can Stock Photo - csp42769298

Peptic Ulcers

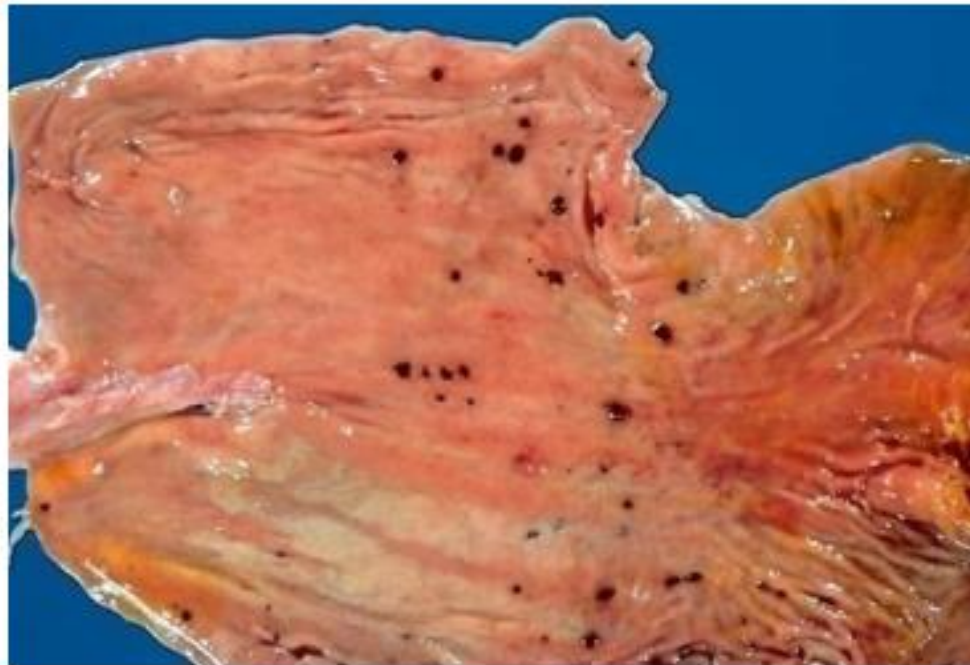


Peptic ulcers:

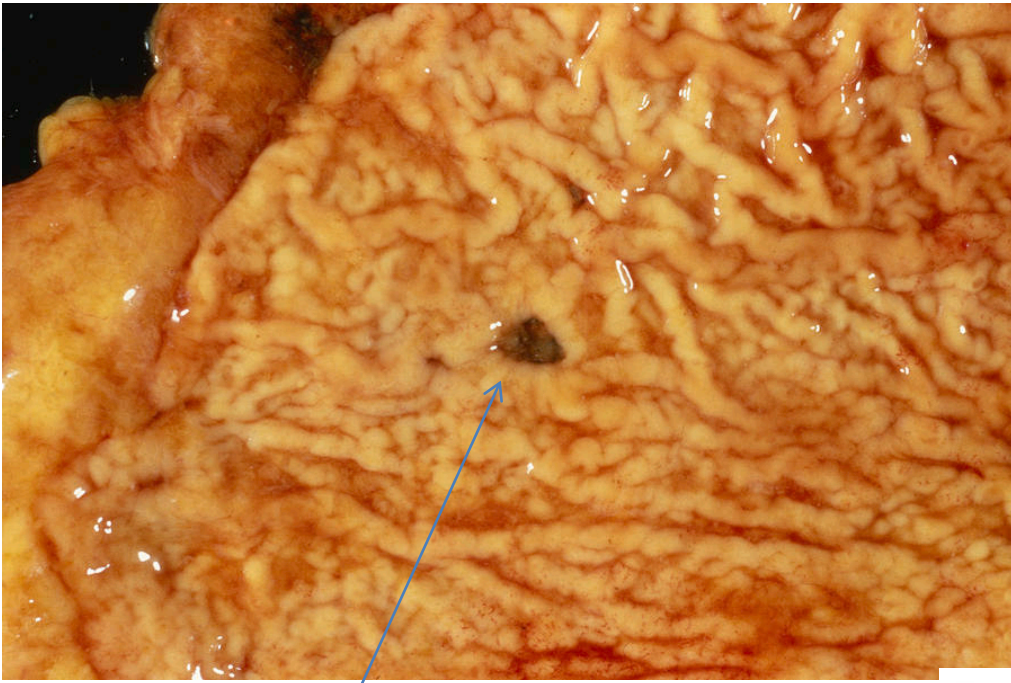
- **An ulcer:** is a discontinuation of the surface epithelium due to necrosis that involving mucosae ,muscularis mucosae , the sub-mucosa, or deeper
- **Acute (peptic) stress ulcer:**
They are multiple, small mucosal erosions, seen most commonly in the stomach but occasionally involving the *duodenum*. It is of two types:

Acute peptic ulcers

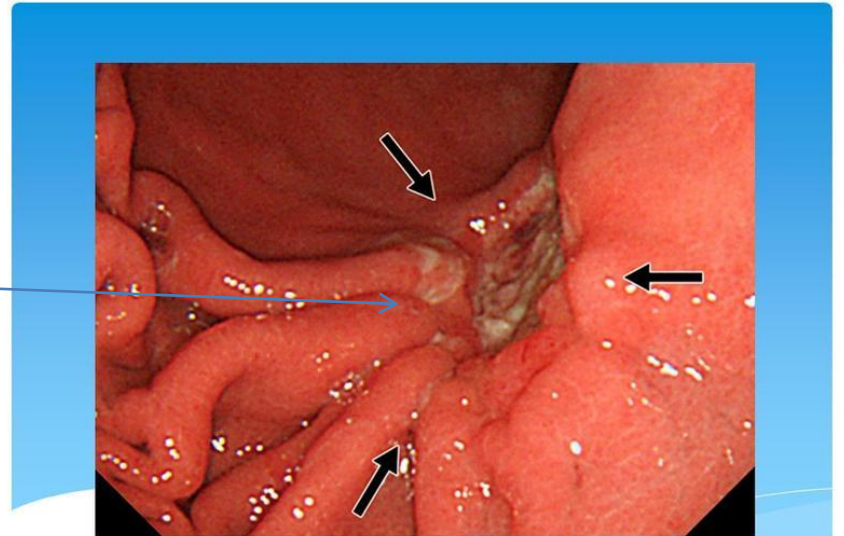
- Acutely developing gastric mucosal defects that may appear after severe stress



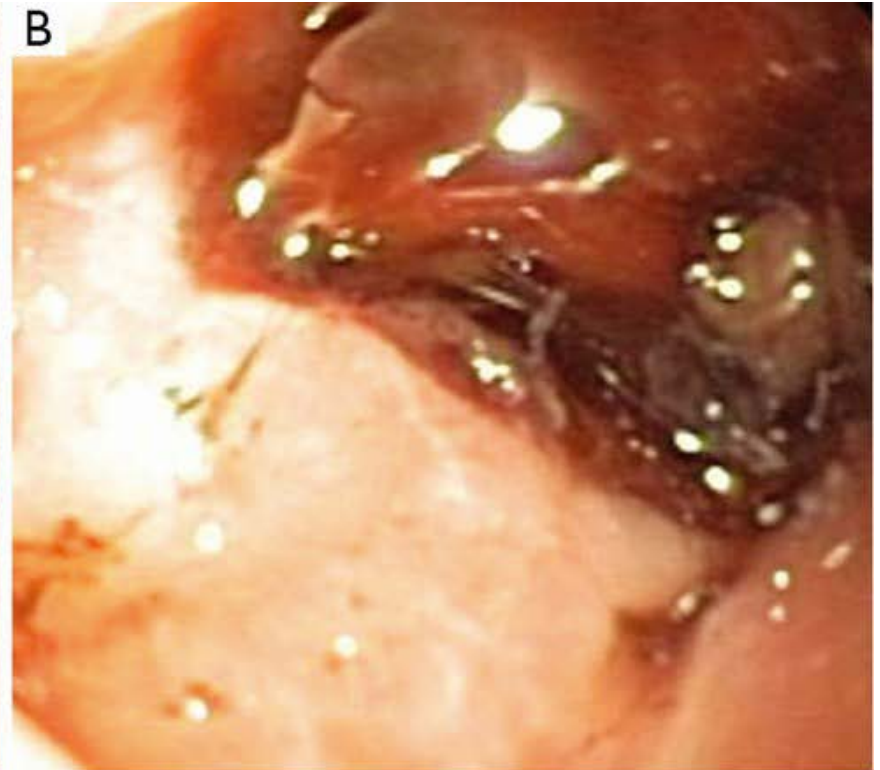
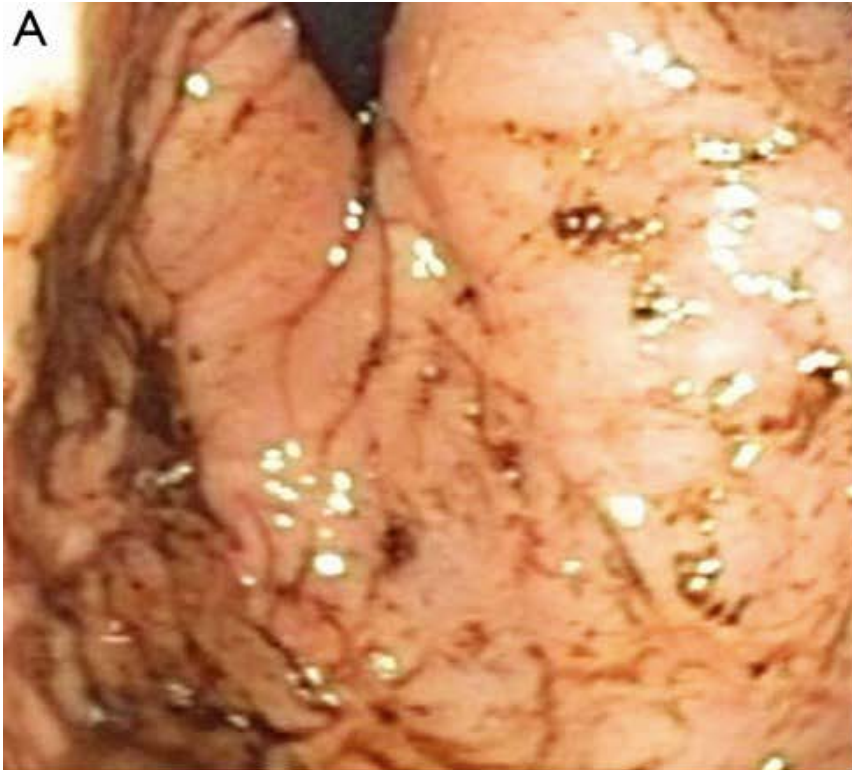
1. *Curling's stress ulcer:* refers to gastro-intestinal ulcerations that develop in relation to major physiologic stress. Persons at high risk for the development of stress ulcers include those with large surface-area burns, trauma, sepsis, acute respiratory distress syndrome, severe liver failure, major surgical procedures.



Curling ulcer of the duodenum

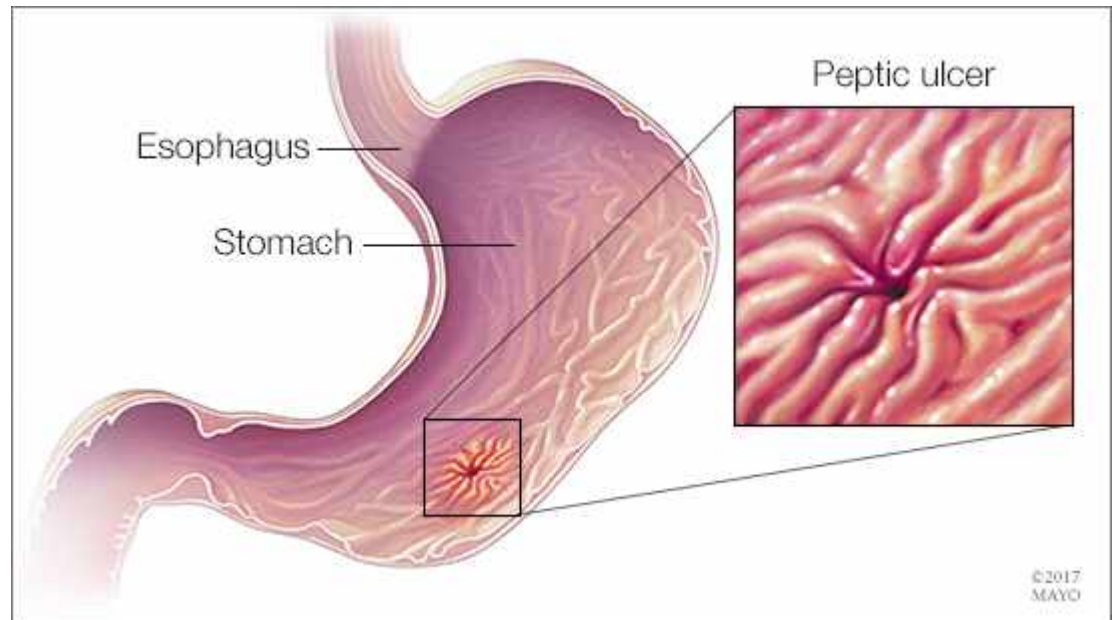
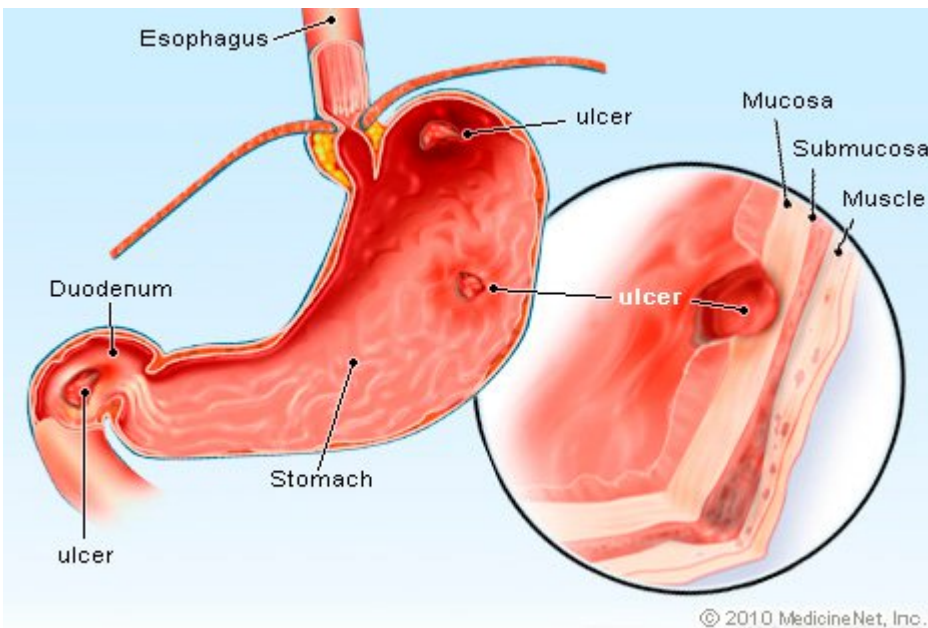


2. Cushing stress ulcer: consists of gastric, duodenal, and esophageal ulcers arising in persons with intracranial injury, operations, or tumors. They are thought to be caused by hypersecretion of gastric acid resulting from stimulation of vagal nuclei by increased intracranial pressure. These ulcers are associated with a high incidence of perforation.



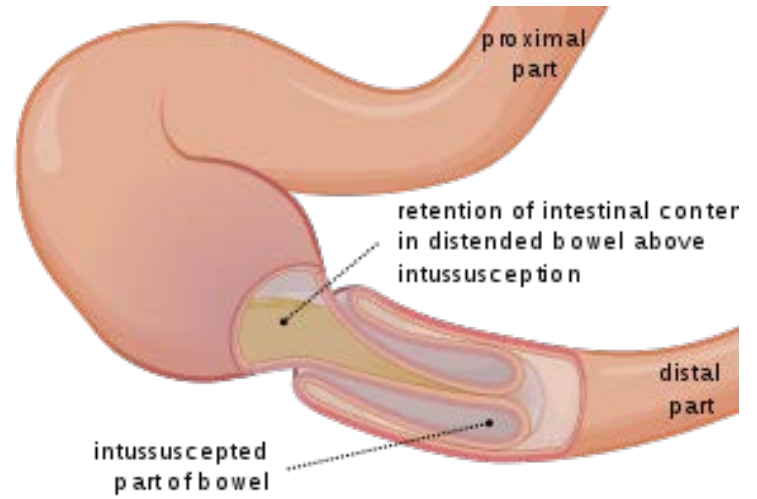
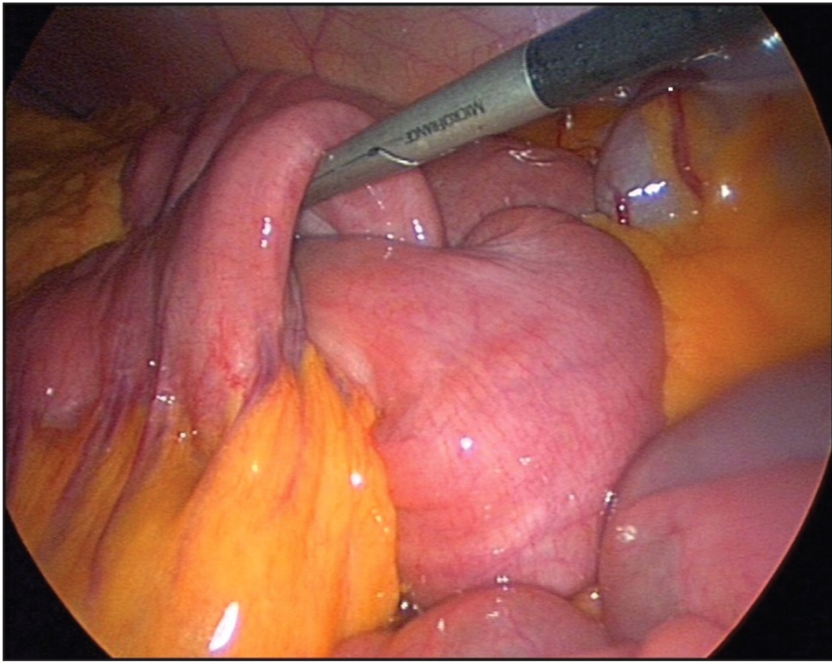
Cushing's stress ulcer

❖ **Peptic ulcers:** degeneration and necrosis of gastrointestinal mucosa due to exposure to acid-peptic (hydrochloric acid and pepsin) secretions. They can occur at any level of the alimentary tract but they occur most commonly (98-99%) in either the duodenum or the stomach in the ratio of 4:1. Each of the two main types may be acute or chronic.

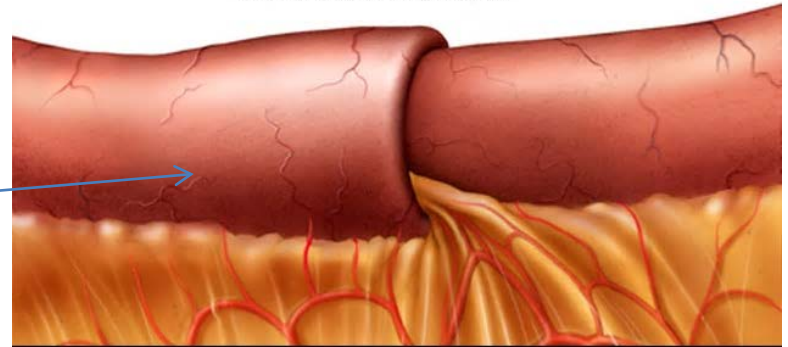


- **INTUSSUSCEPTION:**

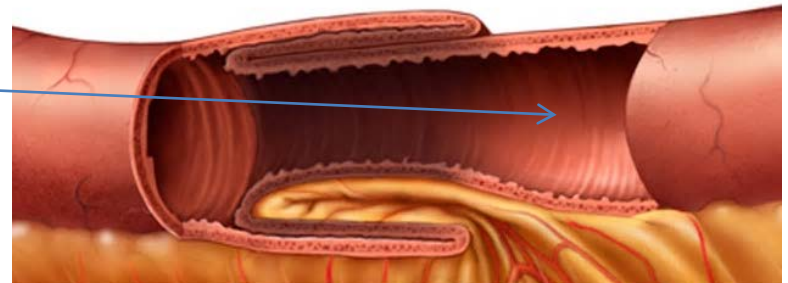
It is the telescoping of a segment of intestine into the segment below due to peristalsis. The telescoped segment is called the *intussusceptum* and lower receiving segment is called the *intussuscipiens*. The condition occurs more commonly in infants and young children. The main *complications* of intussusception are intestinal obstruction, infarction, gangrene, perforation and peritonitis.



Small intestine with intussusception



Intussusception (cross section view)

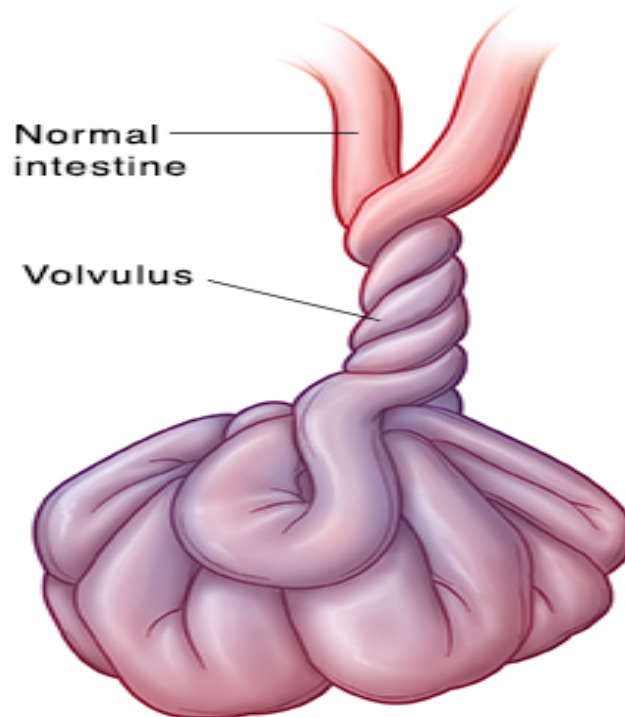


intussusciencie

intussusceptum

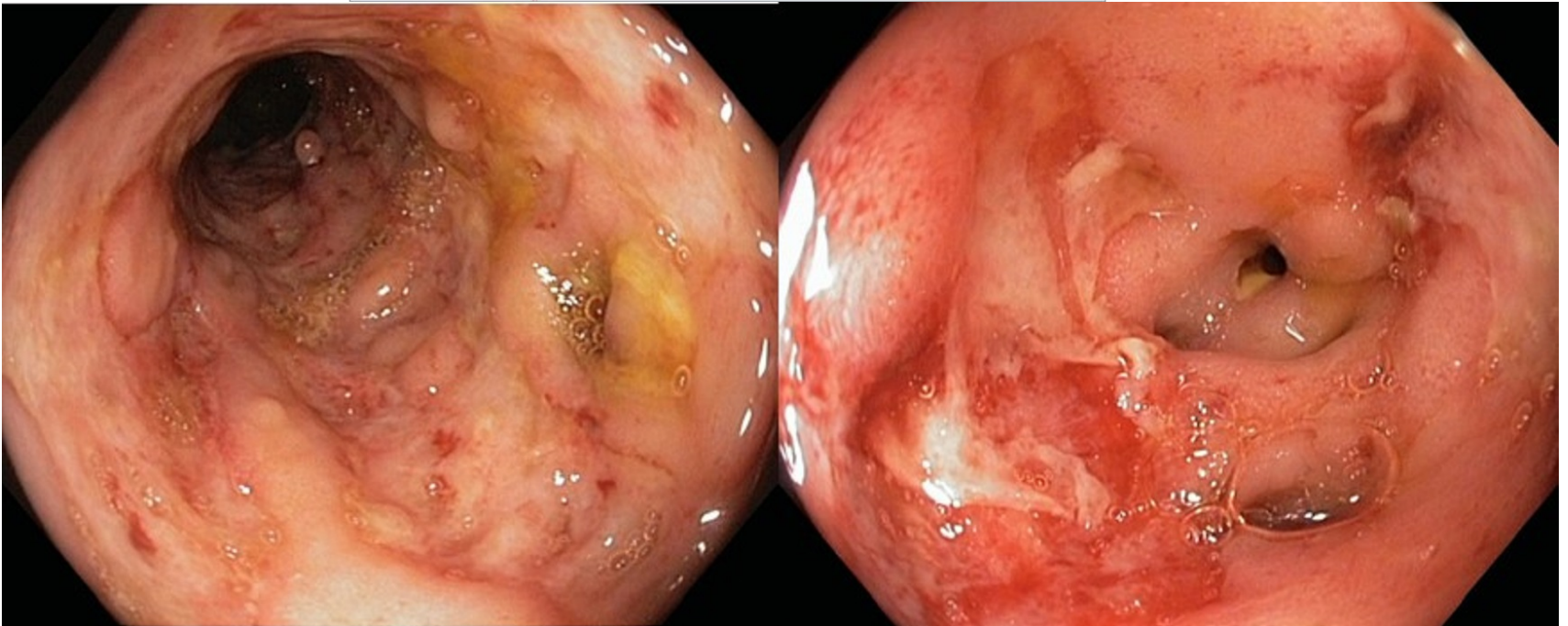
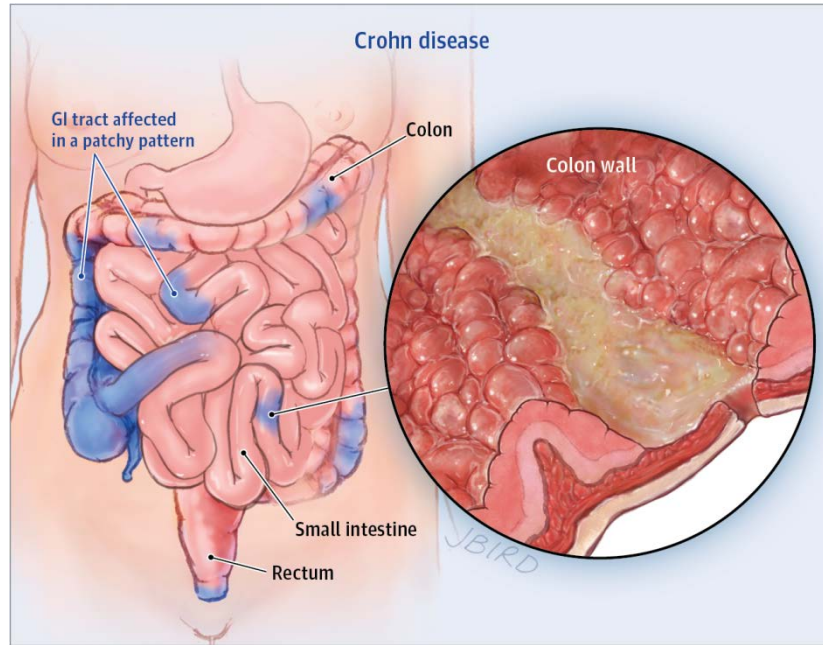
- **VOLVULUS:**

It is the twisting of loop of intestine upon itself through 180° or more. This leads to obstruction of the intestine as well as cutting off of the blood supply to the affected loop. The usual causes are bands and adhesions(congenital or acquired).



Inflammatory bowel disease:

- 1. Crohn's disease or Regional enteritis is an idiopathic chronic ulcerative IBD, characterized by transmural, non-caseating granulomatous inflammation, affecting most commonly the segment of terminal ileum and/or colon, though any part of the gastrointestinal tract may be involved.**

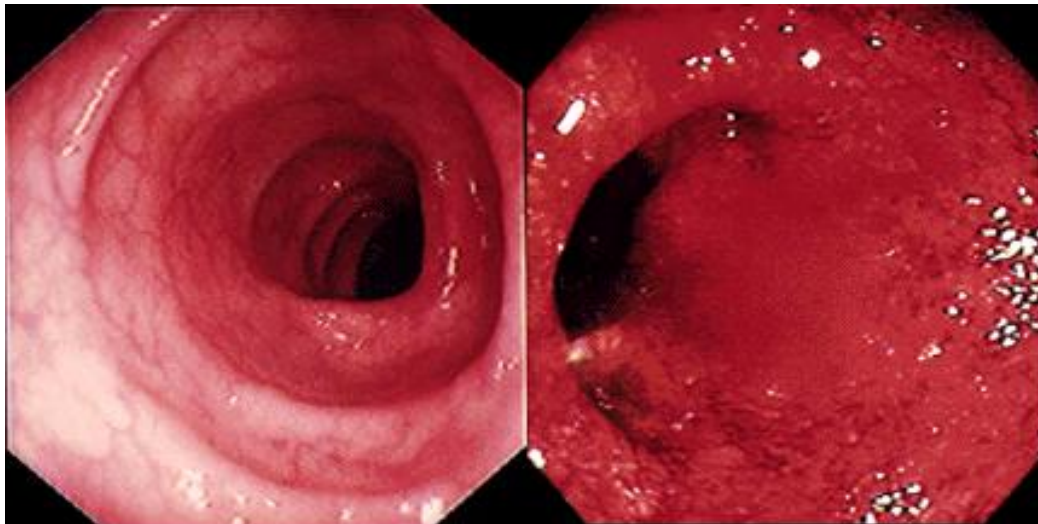
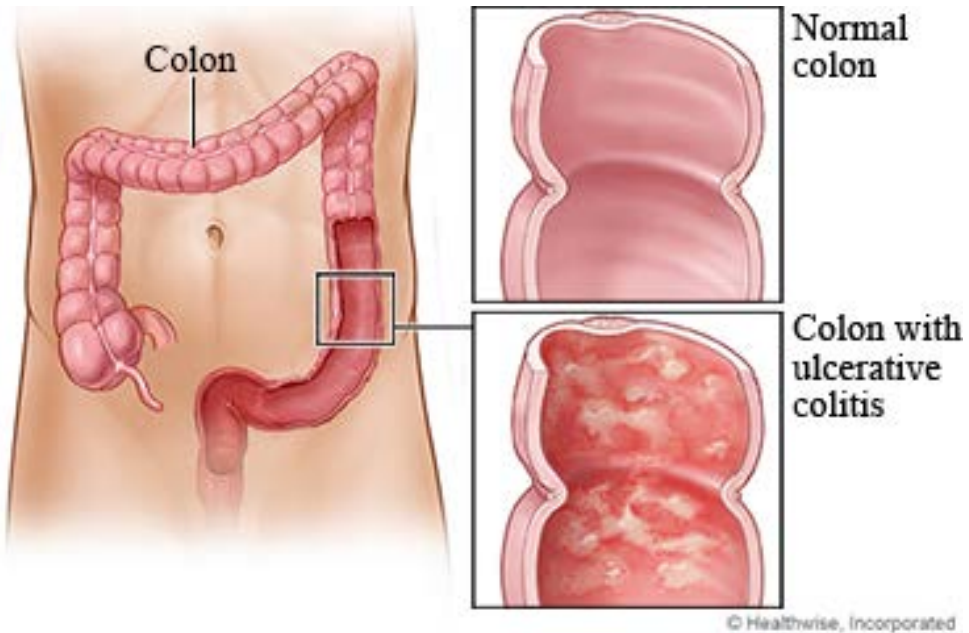


Microscopic examination:

- *Transmural inflammatory cell infiltrate* consisting of chronic inflammatory cells.
- *Non-caseating granulomas* are present in all the layers of the affected bowel wall in 60% of cases.
- There is *patchy ulceration* of the mucosa which may take the form of deep fissures.
- There is *widening of the submucosa* due to oedema and foci of lymphoid aggregates.
- In more chronic cases, *fibrosis* becomes increasingly prominent in all the layers disrupting muscular layer.

- 2. Ulcerative colitis** it is affecting chiefly the mucosa and submucosa of the rectum and descending colon, though sometimes it may involve the entire length of the large bowel.
- **Microscopic examination:**
 - *Crypt distortion, cryptitis* and focal accumulations of neutrophils forming *crypt abscesses*.
 - *Marked congestion, dilatation and haemorrhages.*
 - *Superficial mucosal ulcerations.*

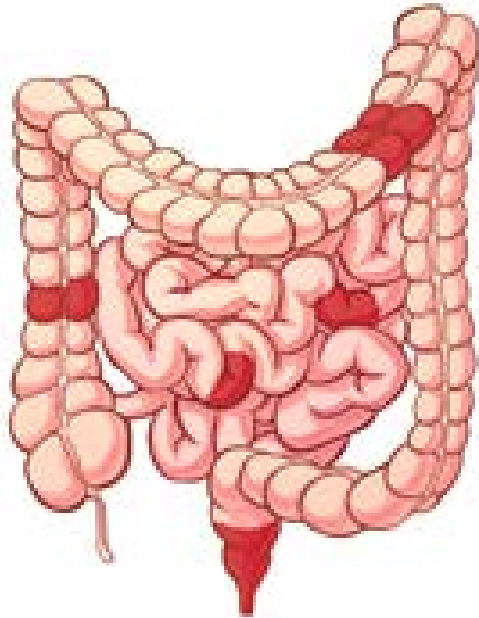
- *Goblet cells* are markedly *diminished* in cases of active disease.
- Areas of *mucosal regeneration* and *muco-depletion* of lining cells.
- In long-standing cases, epithelial *cytologic atypia*, **dysplasia** which may progress to **carcinoma** and **adenocarcinoma**.



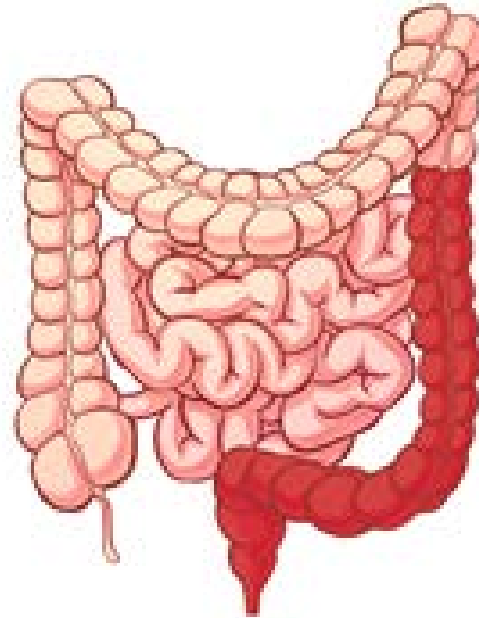
Healthy Colon

Ulcerative Colon

CROHN'S DISEASE

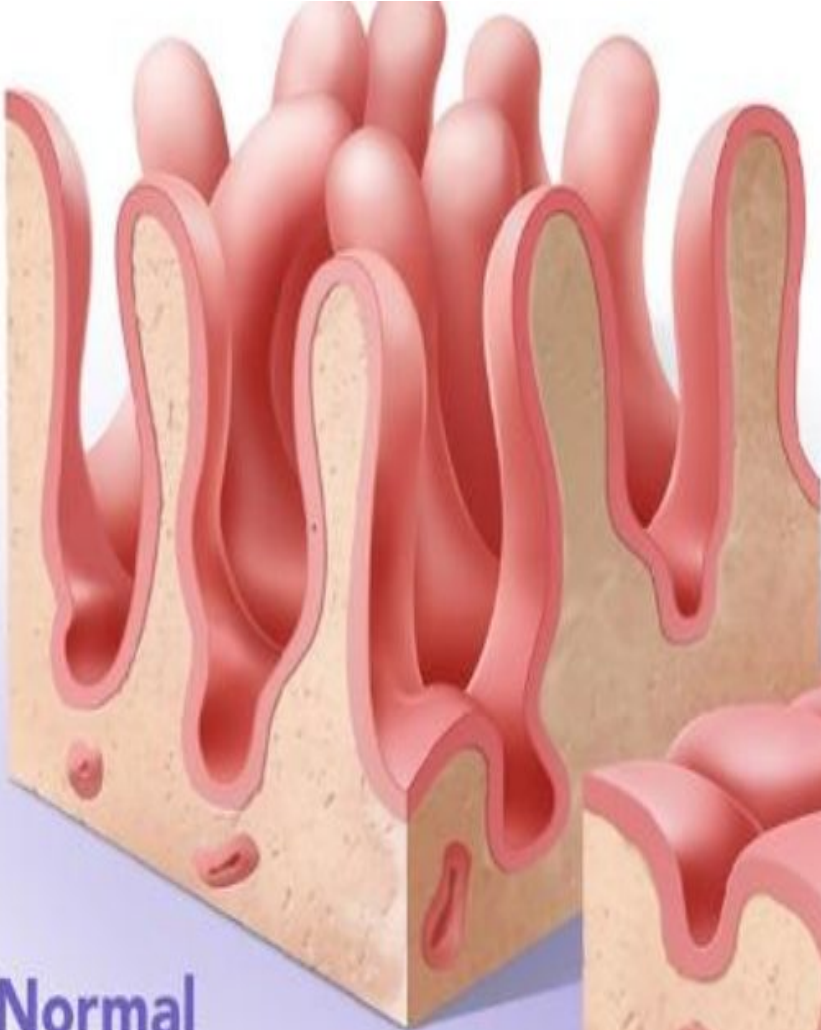


ULCERATIVE COLITIS

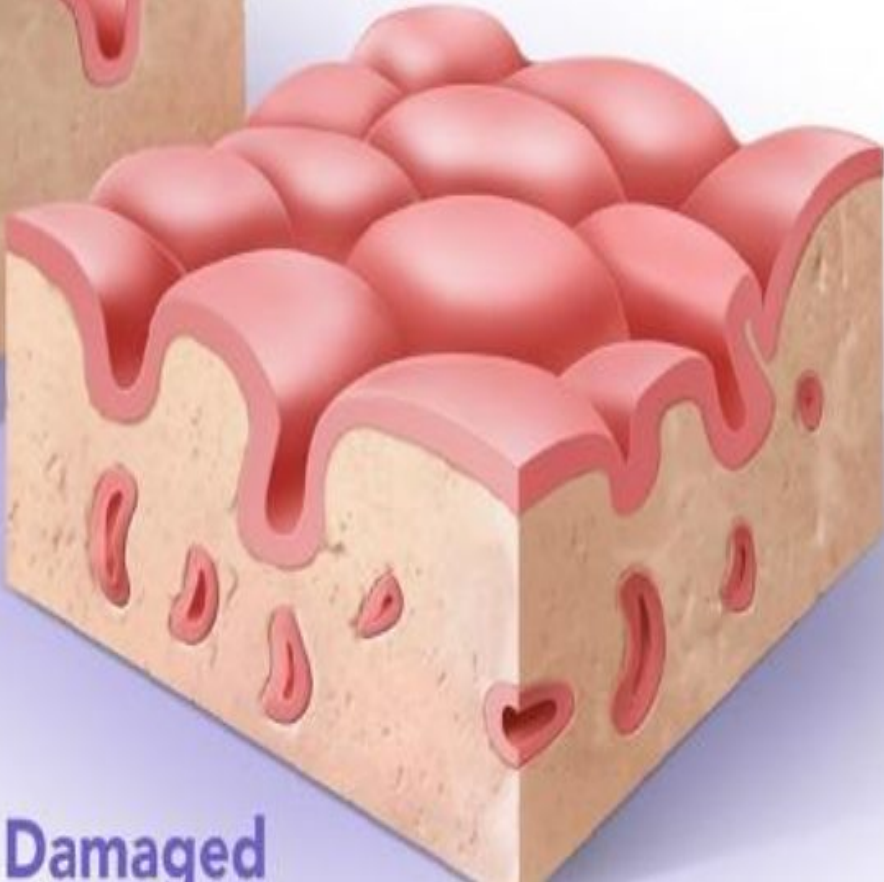


Celiac Disease

Normal



Damaged



- a. **Childhood form**, seen in infants and children and is commonly referred to as *coeliac disease*.
- b. **Adult form**, seen in adolescents and early adult life and used to be called *idiopathic steatorrhoea*.
- In either case, there is genetic abnormality resulting in sensitivity to gluten (a protein) and its derivative, gliadin, present in diets such as grains of wheat, barley and rye.

Microscopic examination:

- **Tissue samples taken from subjects affected by celiac disease mainly show:**
 - **Decreased enterocyte height**
 - **Crypt hyperplasia**
 - **Villous atrophy**
 - **Increased intra-epithelial T lymphocytes.**

