

Mustansiriyah University

College of science

Biology Dept.

Zoology

4th class

Embryology LAB.

(2)

NAME :

The 2nd week—Implantation and formation of bilaminar embryonic disc

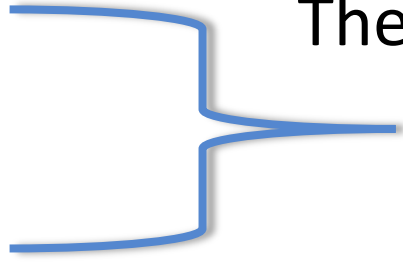
- At this stage the embryo is partly implanted in the endometrium.

The implantation process initiates the **decidual reaction** or **decidualization** in the uterine **stroma**, the cells of which contribute the maternal component of the placenta.

- **The trophoblast** begins to differentiate:
 - **A. CYTOTROPHOBLAST.**
 - its inner part becomes a single layer of cells.
 - **B. SYNCYTIOTROPHOBLAST.**
 - The outer layer is more extensive and is the invasive layer.

- By this stage, **the inner cell mass of the blastocyst** has differentiated into two layers:

- A. Epiblast.



These two layers are in contact and form a bilaminar embryonic disc.

- B. Hypoblast.

-

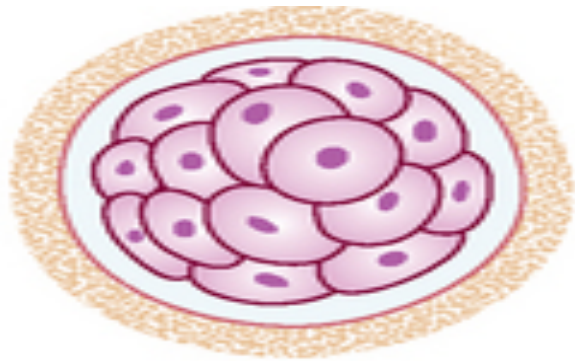
Epiblast:

1. Within the **epiblast** a cavity develops, the **amniotic cavity**, which fills with **amniotic fluid**.
2. Some **epiblast cells** become specialized as **amnioblasts**, and they secrete the **amniotic fluid**.

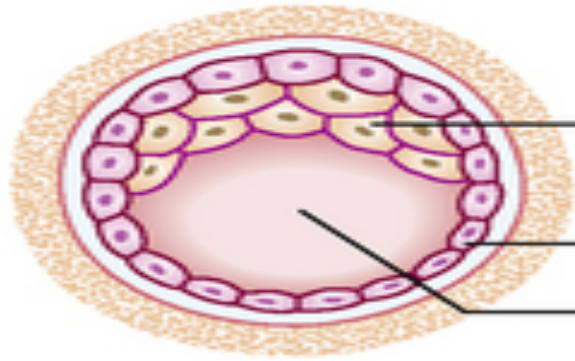
Hypoblast:

- The **exocoelomic membrane** is derived from the hypoblast and lines the cavity that appears beneath the endoderm, **the primary yolk sac**.

A



B

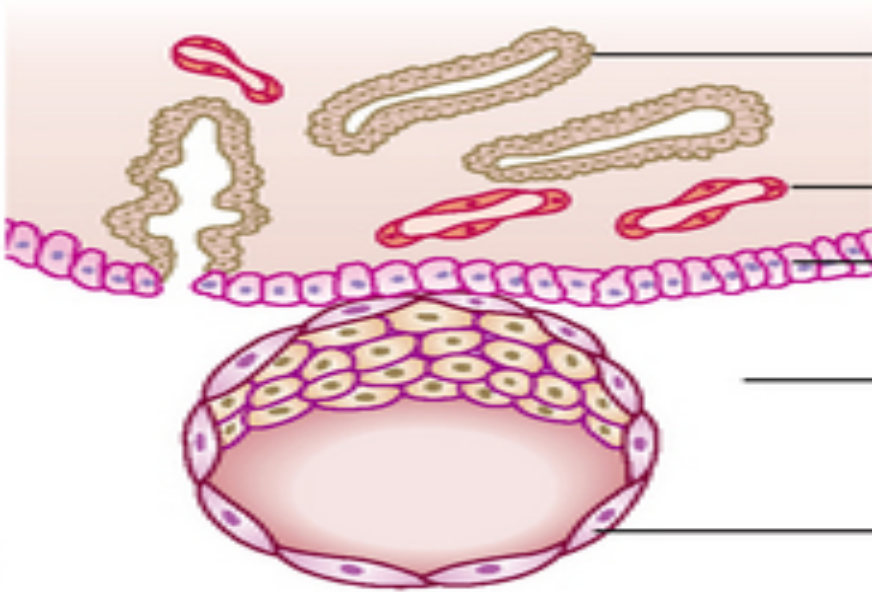


Inner cell mass
(embryoblast)

Trophoblast

Blastocoele

C



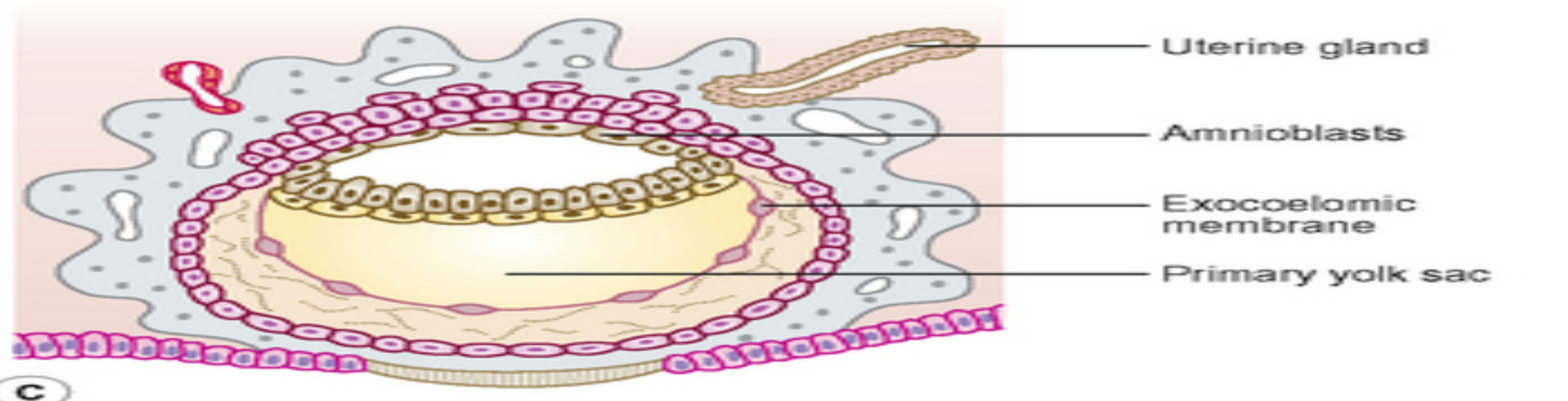
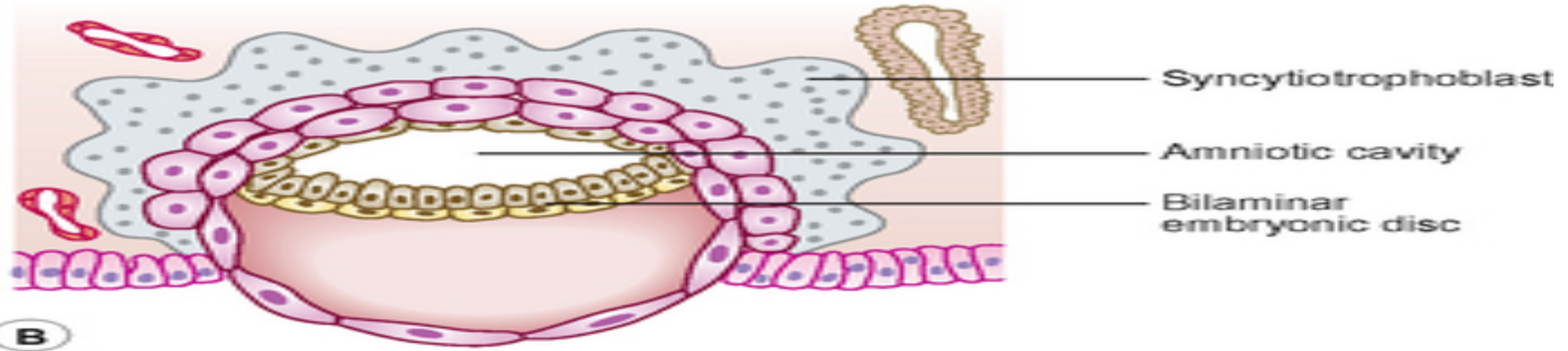
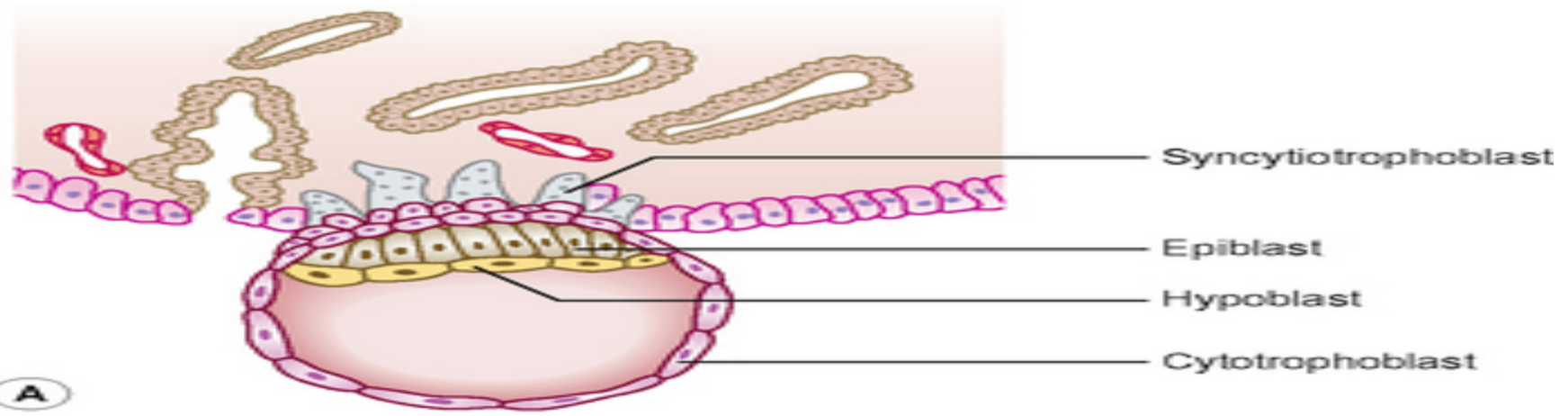
Endometrial gland

Endometrial capillary

Uterine epithelium

Uterine cavity

Trophoblast



- The fluid contained in this sac is the source of nutrition for the embryo before the placenta is fully formed and functional.
- By 12 days there has been significant change in the trophoblast.
 1. Small clefts appear in the syncytiotrophoblast called **lacunae** which deriving nutritional support for the developing embryo.
 - 2. Clefts appear between the exocoelomic membrane and the cytotrophoblast These merge to form the **extra-embryonic coelom** and this cavity comes to almost completely surround the embryo. This is the **chorionic cavity**.

- By day 13 the lacunae have enlarged further.
- The cytotrophoblast has begun to form **primary chorionic villi**.
- The embryo proper consists of two layers, **the epiblast and the hypoblast**, still closely applied to each other. The two cavities continue to enlarge, with **the amniotic cavity above the epiblast** and **the yolk sac below the hypoblast**, now known as the **secondary yolk sac** because of the presence of the chorionic cavity.
- The embryo is connected to the cytotrophoblast by a **connecting stalk**, This stalk is the indication of the umbilical cord.

- By the end of the second week the syncytiotrophoblast produces the hormone **human chorionic gonadotrophin (HCG)**, which maintains the **corpus luteum** in the ovary, which in turn sustains the thickness of the endometrium. **The hormone is secreted in the urine and thus its presence is an early indicator of pregnancy. This is the basis upon which pregnancy test kits work.**

