

LAB 4


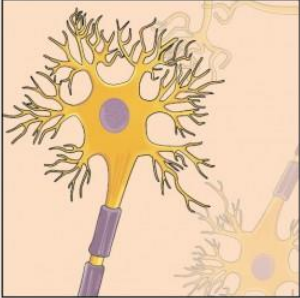
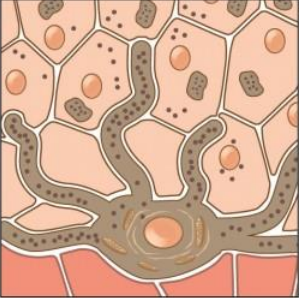


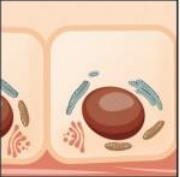



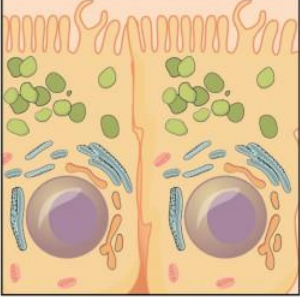
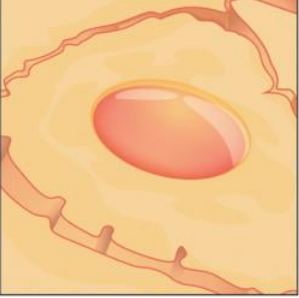
The term **tissue** is used to describe a group of cells that are similar in structure and perform a specific function. **Histology** is the the field of study that involves the microscopic examination of tissue appearance, organization, and function.

Tissues are organized into four broad categories based on structural and functional similarities. These categories are (**epithelial, connective, muscle, and nervous**). The primary tissue types work together to contribute to the overall health and maintenance of the human body. Thus, any disruption in the structure of a tissue can lead to injury or disease.

Embryonic Origin of Tissues

The zygote, or fertilized egg, is a single cell formed by the fusion of an egg and sperm. After fertilization the zygote gives rise to rapid mitotic cycles, generating many cells to form the embryo. The first embryonic cells generated have the ability to differentiate into any type of cell in the body. As cell proliferation progresses, three major cell lineages are established within the embryo. Each of these lineages of embryonic cells forms the distinct germ layers from which all the tissues and organs of the human body eventually form. Each germ layer is identified by its relative position: **ectoderm** (*ecto-* = “outer”), **mesoderm** (*meso-* = “middle”), and **endoderm** (*endo-* = “inner”).

- 1- **Epithelial tissue**
- 2- **Connective tissue**
- 3- **Muscular tissue**
- 4- **Nervous tissue**

Germ Layer	Gives rise to:
Ectoderm	<p data-bbox="446 283 1388 346">Epidermis, glands on skin, some cranial bones, pituitary and adrenal medulla, the nervous system, the mouth between cheek and gums, the anus</p> <div style="display: flex; justify-content: space-around; align-items: center;"> <div style="text-align: center;">  <p data-bbox="548 695 651 722">Skin cells</p> </div> <div style="text-align: center;">  <p data-bbox="873 695 959 722">Neurons</p> </div> <div style="text-align: center;">  <p data-bbox="1170 695 1300 722">Pigment cell</p> </div> </div>
Mesoderm	<p data-bbox="446 766 1388 829">Connective tissues proper, bone, cartilage, blood, endothelium of blood vessels, muscle, synovial membranes, serous membranes lining body cavities, kidneys, lining of gonads</p> <div style="display: flex; justify-content: space-around; align-items: center;"> <div style="text-align: center;">  <p data-bbox="500 1050 581 1102">Cardiac muscle</p> </div> <div style="text-align: center;">  <p data-bbox="690 1050 771 1102">Skeletal muscle</p> </div> <div style="text-align: center;">  <p data-bbox="863 1050 977 1102">Tubule cell of kidney</p> </div> <div style="text-align: center;">  <p data-bbox="1070 1050 1183 1102">Red blood cells</p> </div> <div style="text-align: center;">  <p data-bbox="1260 1050 1341 1102">Smooth muscle</p> </div> </div>
Endoderm	<p data-bbox="446 1144 1388 1207">Lining of airways and digestive system except the mouth and distal part of digestive system (rectum and anal canal); glands (digestive glands, endocrine glands, adrenal cortex)</p> <div style="display: flex; justify-content: space-around; align-items: center;"> <div style="text-align: center;">  <p data-bbox="548 1547 651 1575">Lung cell</p> </div> <div style="text-align: center;">  <p data-bbox="873 1547 976 1575">Thyroid cell</p> </div> <div style="text-align: center;">  <p data-bbox="1170 1547 1300 1575">Pancreatic cell</p> </div> </div>

1-Epithelial tissue

Epithelium is divided into two types:

a. Simple epithelium:

- 1) One cell layer thick
- 2) All cells rest on the basement membrane (basal surface) and all cells face the free surface.
- 3) Types of simple epithelium are: Squamous, Cuboidal, Columnar, Pseudo stratified.

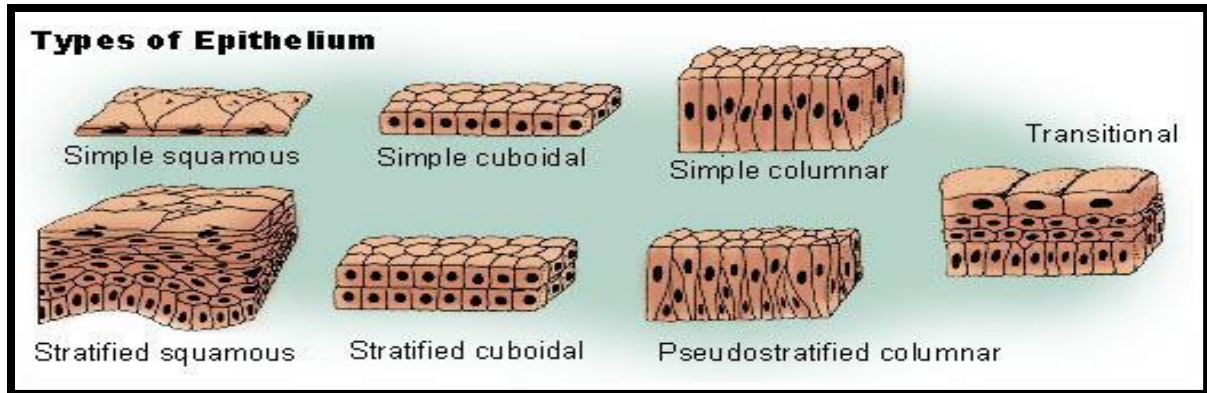
Pseudostratified Epithelial cells: cells become so crowded that some of the nuclei become displaced and several rows of nuclei appear in sections of the cell sheet, even though each cell is still attached to the basement membrane. Commonly found along the respiratory airways; the cilia of these epithelia propel mucous and particles toward the pharynx and out of the airways.

b. Stratified epithelium:

- 1) More than one cell layer thick
- 2) Only the deepest layer of cells contacts the basement membrane and only the superficial-most cells have a free surface.
- 3) Types of stratified epithelium are: Squamous, Cuboidal, Columnar and Transitional.

Transitional epithelium cell: is a type of tissue that changes shape in response to stretching. The transitional epithelium usually appears cuboidal when relaxed and squamous when stretched. This tissue consists of multiple layers of epithelial cells which can contract and expand in order to adapt to the degree of distension needed.

Transitional epithelium lines the organs of the urinary system , the bladder, for example, has a need for great distension.



Connective tissue

The connective tissue has an important function include **connecting**, **supporting** and **protection**.

Structure of Connective Tissue:

1. Ground substance: A clear, colorless, and viscous fluid

In bone the ground substance includes minerals.

In blood, the ground substance is fluid (plasma).

2. Fibers: Together the ground substance and fibers make up the extracellular matrix.


3. Cells: are spread through an extracellular fluid.

Classification of connective tissue:

Proper connective tissue

1-Loose connective tissue: Loose connective tissue is found between many organs where it acts both to absorb shock and bind tissues together. **areolar** web-like. It fills the spaces between muscle fibers, surrounds blood and lymph vessels, and supports organs in the abdominal cavity. , **reticular** is a mesh-like, supportive framework for soft organs such as lymphatic tissue, the spleen, and the liver and **adipose**. consists mostly of fat storage cells.

2-Dense connective tissue: Dense connective tissue contains more collagen fibers than does loose connective tissue. It displays greater resistance to stretching and a higher tensile strength. There are three major categories of dense connective tissue: **regular** fibers are parallel to each other, **irregular**, the arrangement of proteins fibers is irregular and **elastic** contains elastin fibers in addition to collagen fibers, which allows the tissue to return to its original length after stretching. found in structures such as tendons and ligaments,



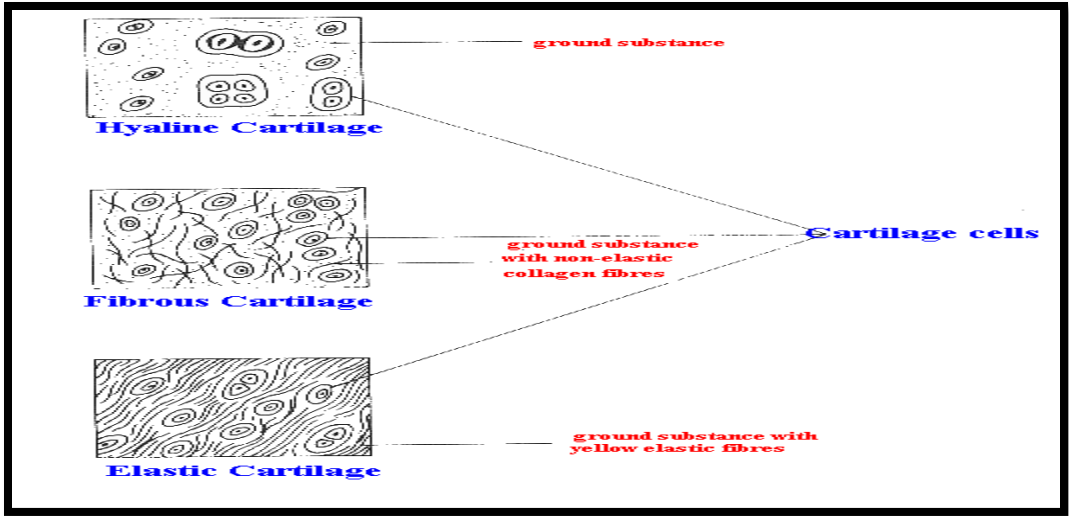
Special Connective tissue

1-Cartilage: There are three types of cartilage:

hyaline the most common type it is found in the rib cage and nose and covers bones where they meet to form moveable joints. It forms the template of the embryonic skeleton before bone formation.,

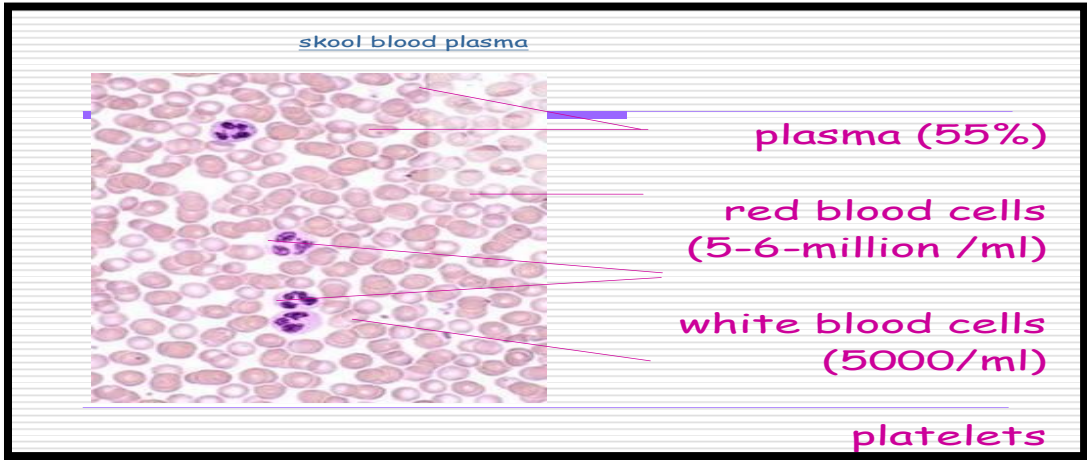
fibro The intervertebral discs are examples of fibro cartilage

elastic. The external ear contains elastic cartilage.



2-Bone: Bone is the hardest connective tissue. It provides protection to internal organs and supports the body. There are two types of bone: **compact** and **spongy**

3- Blood: Consists of formed elements (cells) Are erythrocytes (RBCs) , leukocytes (WBCs)& platelets suspended & carried in plasma (fluid part)




Red blood cells

Red blood cells (RBCs), also known as erythrocytes, RBCs are flattened biconcave discs, Lack nuclei & mitochondria

Have two main functions:

1. To pick up oxygen from the lungs and deliver it to tissues elsewhere.
2. To pick up carbon dioxide from other tissues and unload it in the lungs.

RBCs contain a protein called Haemoglobin. This combines with oxygen to form Oxyhaemoglobin. Each RBC has a lifespan of approximately 120 days before it gets broken down by the spleen. New cells are manufactured in the bone marrow of most bones. There are approximately 5-6 million red cells per ml of blood.



White blood cells

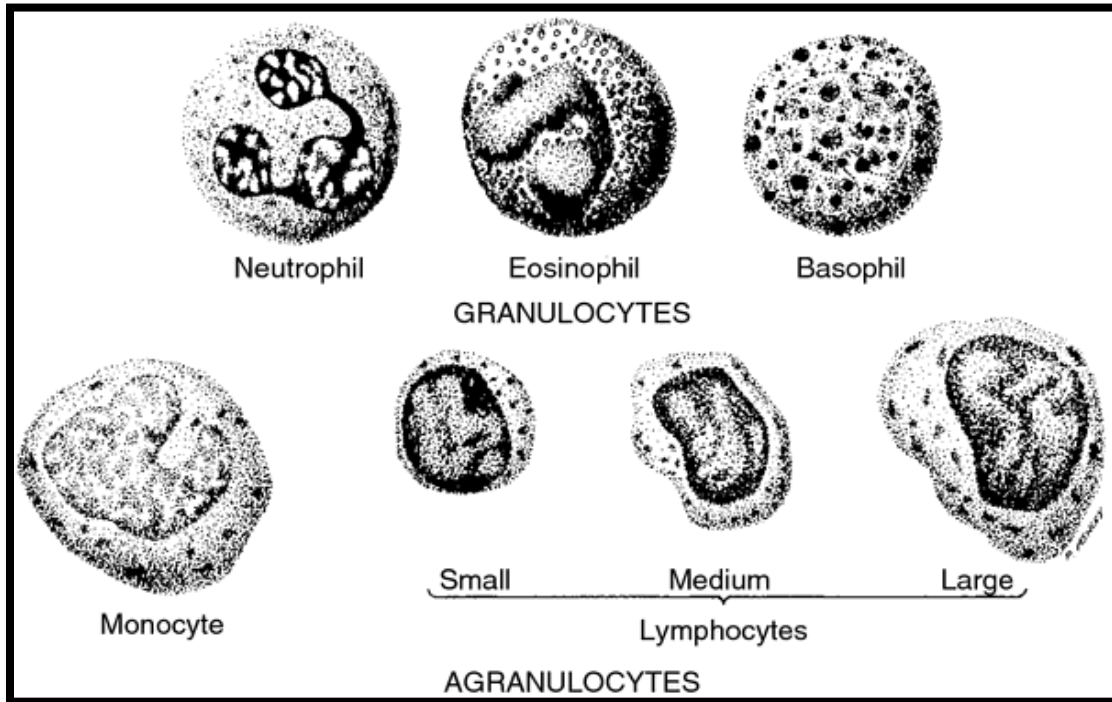
also called **immune cells** or **immunocytes**, are involved in protecting the body against infectious disease . White blood cells are generally larger than red blood cells. They include.

1. Granular leukocytes.

Include: eosinophils, basophils & neutrophils

2. Agranular leukocytes.

Include: lymphocytes & monocytes



Platelets (thrombocytes): They aggregate together during the process of blood coagulation and clotting. Platelets are small (2-5 μm), have no nucleus and are ovoid shaped.

