

## Lab (6)

**Kingdom:** Protista

**Subkingdom:** Protozoa

**Phylum:** Sarcomastigophora

**Class:** Ampicomplexa (sporozoa)

**Order:** Eucoccida

**Family:** Plasmodidae

**Genus:** *Plasmodium vivax* (benign tertian malaria).

*Plasmodium malaria* (quartan malaria).

*Plasmodium ovale* (ovale tertian malaria).

*Plasmodium falsiparum* (malignant tertian malaria).

**Disease name:** Malaria

**Site of infection:** Red blood cell and Liver tissue cell

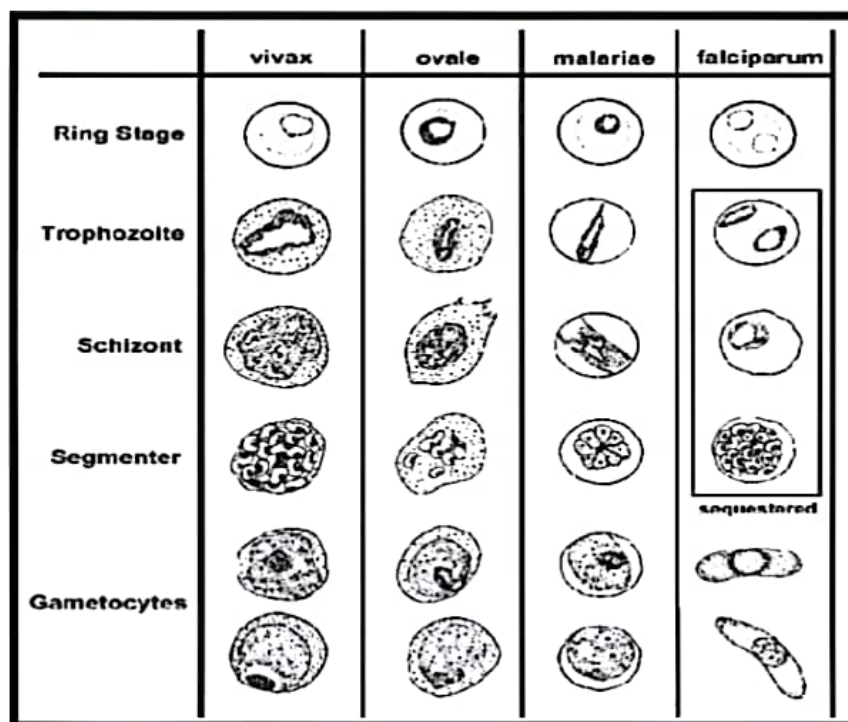
***Plasmodium* requires two hosts:**

**-Definitive invertebrate host:** (vector Anopheles mosquitoes female).

**-Intermediate vertebrate host:** (mammals, birds and lizards).

**Morphology:**

	<u>P.falciparum</u>	<u>P.malaria</u>	<u>P. vivax</u>	<u>P.ovalae</u>
<u>Trophozoite</u>	ring forms	band form	amoeboid form	compact rings in cells
<u>Schizont</u>	(8 – 36) merozoites.	(6–12) large merozoites	(16). merozoites	(6-12) merozoites
<u>Microgametocyte</u>	Larger than RBC, kidney shaped with blunt round ends	Smaller than RBC, round compact	Fills enlarged RBC, small round or oval, compact with central nucleus	Of the size of RBC round, compact
<u>Macrogametocyte</u>	more slender and longer than the male	Round or oval with peripheral nucleus	large round or oval with peripheral nucleus	Round or oval with peripheral nucleus



## Life cycle:

### sexual cycle

occurs in mosquito (9-21 days), fusion of micro and macrogametes are infective for mosquito → zygote → ookinete (~24 hours) → oocyst

Asexual replication (sporogony) → sporozoites released → migrate through hemocoel → invade salivary glands

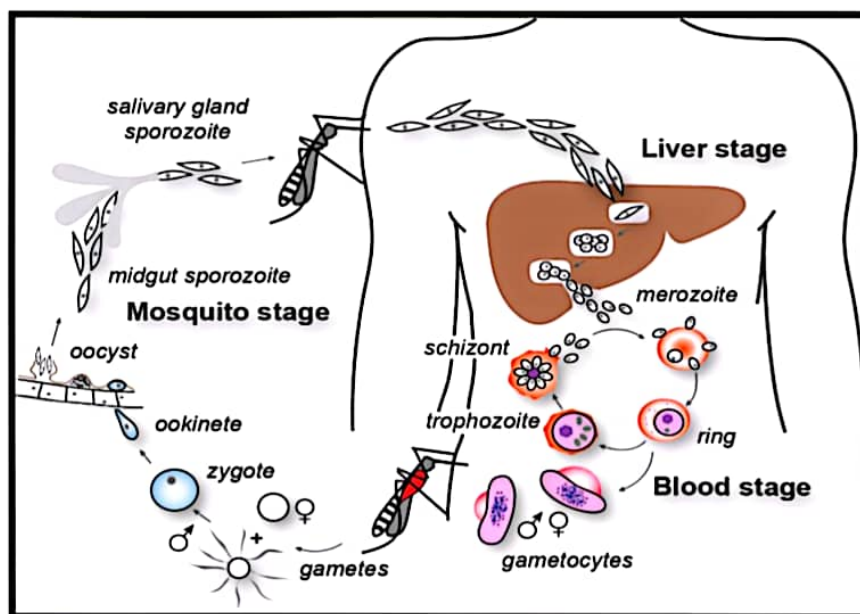
### Asexual cycle

#### 1-Exoerythrocytic schizogony (Liver stage)

Sporozoites injected during mosquito feeding → merozoites (uninucleate asexual stages) invade liver cells. After this initial replication in the liver (exo-erythrocytic schizogony) the parasites undergo asexual multiplication in the erythrocytes.

#### 2-Erythrocytic schizogony (Blood stage)

Merozoites infect red blood cells and form the ring stage in it and transform into trophozoites that mature into schizonts (multinucleated asexual stages), which rupture releasing merozoites. Some parasites differentiate into asexual erythrocytic stages (gametocytes) repeated erythrocytic schizogony (48hr) in *Pf.*, *Py.*, *Po* and (72 hr) in *Pm*.



### Symptoms:

- **Fever:** Often irregular. The regular pattern of fever does not occur until the illness has continued for a week or more.
- **Anemia:** The anemia is hemolytic in type. It is more severe in infections with *P. falciparum* because in this infection cells of all ages can be invaded.
- **Splenomegaly:** The spleen enlarges early in the acute attack of malaria.
- **Jaundice:** Mild jaundice due to hemolysis may occur in malaria.

### Diagnosis:

- 1-Thin blood films stained with Giemsa stain.
- 2-Antibody test.